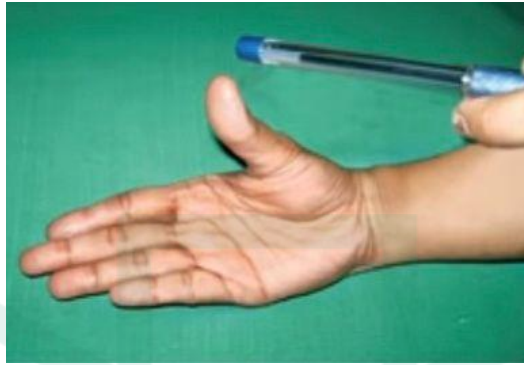

## Anatomy

1. Pen Test is for which nerve



- A. Median Nerve
- B. Ulnar nerve
- C. PIN
- D. Musculocutaneous

**Answer: A** Median Nerve

### Explanation

The doctor places a **small needle electrode into muscles** in your hand and arm that get impulses from the median nerve. The needle sends electric impulses into the muscle. You relax and flex your hand several times. The doctor can tell if your median nerve is damaged or being squeezed.

---

2. **A small boy with multiple fracture of Humerus following which there is loss of sensation over lateral side of forearm, difficulty in flexion of elbow & supination of forearm.**

- A. Musculocutaneous nerve
- B. Median nerve
- C. Axillary
- D. Radial nerve

**Answer: A** Musculocutaneous nerve

**Explanation**

- Nerve roots – C5-C7.
  - Motor functions – muscles in the anterior compartment of the arm (coracobrachialis, biceps brachii and the brachialis).
  - Sensory functions – gives rise to the lateral cutaneous nerve of forearm, which innervates the lateral aspect of the forearm.
  - These muscles flex the upper arm at the shoulder and the elbow. In addition, the biceps brachii also supinates the forearm.
- 

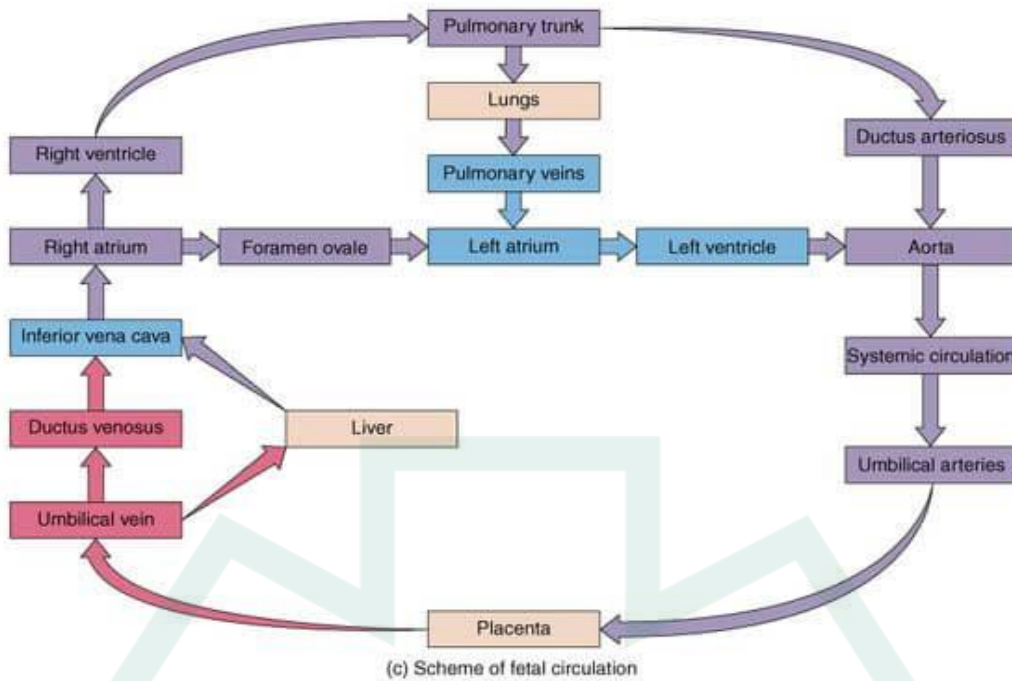
**3. Which blood vessel carries deoxygenated blood back to placenta**

- A. Umbilical Artery
- B. Umbilical vein
- C. Uterine artery
- D. Descending aorta

**Answer <A:Umbilical artery**

**Explanation:**

The umbilical arteries carry deoxygenated fetal blood toward the placenta for replenishment, and the umbilical vein carries newly oxygenated and nutrient-rich blood back to the fetus.



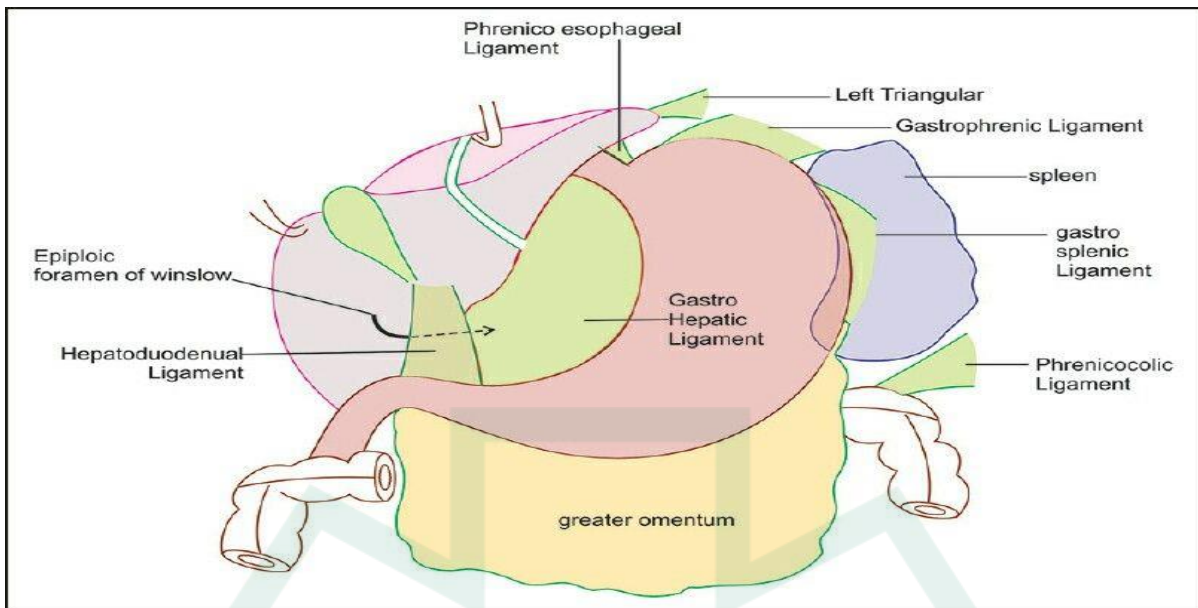
#### 4. Structure preventing vertical descent of spleen

- A. Phrenocolic ligament
- B. Hepatogastric ligament
- C. Ligamentum teres
- D. Ligamentum flavum

**Answer <A:Phrenocolic ligament.**

**Explanation:**

The phrenocolic ligament is continued from the left colic flexure to the thoracic diaphragm opposite the tenth and eleventh ribs; it passes below and serves to support the spleen. This ligament marks the site where the colon exits the peritoneal cavity: the phrenocolic ligament so is an important point of intersection of abdominal anatomy and, consequently, a crucial point for spread of abdominal disease.



5. Which nerve is required for GAG reflex

- A. 9th cranial nerve
- B. 10th cranial nerve
- C. 11th cranial nerve
- D. 12th cranial nerve

**Answer <A:9th cranial nerve**

**Explanation:**

The gag reflex, also called the pharyngeal reflex, is a contraction of the throat that happens when something touches the roof of the mouth, the back of the tongue or throat, or the area around the tonsils. This reflexive action helps to prevent choking. The afferent nerve for gag reflex is glossopharyngeal nerve and efferent nerve is vagus nerve.

6. The Great saphenous vein graft was used for a patient in CABG. Post surgery the patient is having a neuralgia on the medial aspect of leg and foot. Which nerve has been injured?

- A. Saphenous Nerve
- B. Femoral vein
- C. Profunda femoris vein
- D. Popliteal vein

**Answer < A:**Saphenous vein

**Explanation:**

Saphenous neuralgia after harvest of GSV for CABG is common. The main symptom is anaesthesia and certain areas may persist for some considerable time post-operatively. Hyperaesthesia and pain, for the early onset and the early disappearance, are considered as a normal consequence of surgical procedure from around 5 days to 8 weeks and anaesthesia does not last longer than 2 months.

---

**Physiology**

7. Beta 2 receptors act via following secondary messenger

- A. Adenylate Cyclase
- B. Tyrosine kinase receptors
- C. TGF-beta receptors
- D. Cytokine receptors

**Answer < A:**Adenylate Cyclase for beta-2 receptors.

**Explanation:**

Activation of  $\beta$  adrenergic receptors leads to relaxation of smooth muscle in the lung, and dilation and opening of the airways.  $\beta$  adrenergic receptors are coupled to a stimulatory G protein of adenylyl cyclase. This enzyme produces the second messenger cyclic adenosine monophosphate (cAMP).

---

**8. A child presented with dehydration and was supplemented with ORS solution for management. Which of the following receptors help in the absorption of glucose from GIT?**

- A. SGLT 1
- B. SGLT 2
- C. GLUT 1
- D. GLUT 2

**Answer < A:**SGLT 1

**Explanation:**

Majority of glucose is absorbed via GLUT transporters in the body. However, the exception for this is the GIT and the Kidneys, where it is absorbed via the SGLT 1 and SGLT 2 receptors, which act as Sodium Glucose Co-transporters. Since ORS has both sodium and glucose, it is absorbed from the intestinal cell from the lumen via SGLT 1 receptors.

---

**9. A patient presented with cold skin, fatigue, shortness of breath with activity and enlarged liver. His JVP was measured which showed higher amplitude of “a” wave JVP is due to**

- A. Tricuspid Regurgitation
- B. Tricuspid Stenosis
- C. Mitral Regurgitation
- D. Mitral Stenosis

**Answer < B:**Tricuspid Stenosis

**Explanation:**

The a wave of JVP represents the atrial systole. Stenosis of the tricuspid valve leads to increase in right atrial pressure.

Cannon a wave is seen in AV dissociation from heart block (intermittent).

A wave is absent in atrial fibrillation.

---

**10. The body fluid compartments of a patient were measured, which showed the following values:**

**Na-10**

**K-140**

**Cl-15**

**Name the fluid compartment.**

- A. Interstitial fluid
- B. ECF
- C. ICF
- D. Total body fluid

**Answer < C:ICF**

**Explanation:**

The given values show low sodium and high potassium levels. ECF always has higher sodium concentration than IC. Hence the given fluid compartment is ICF.

---

**11. An elderly female presented with dribbling of urine only on coughing and straining. What type of urinary incontinence is she suffering from?**

- A. Stress incontinence
- B. Urge incontinence

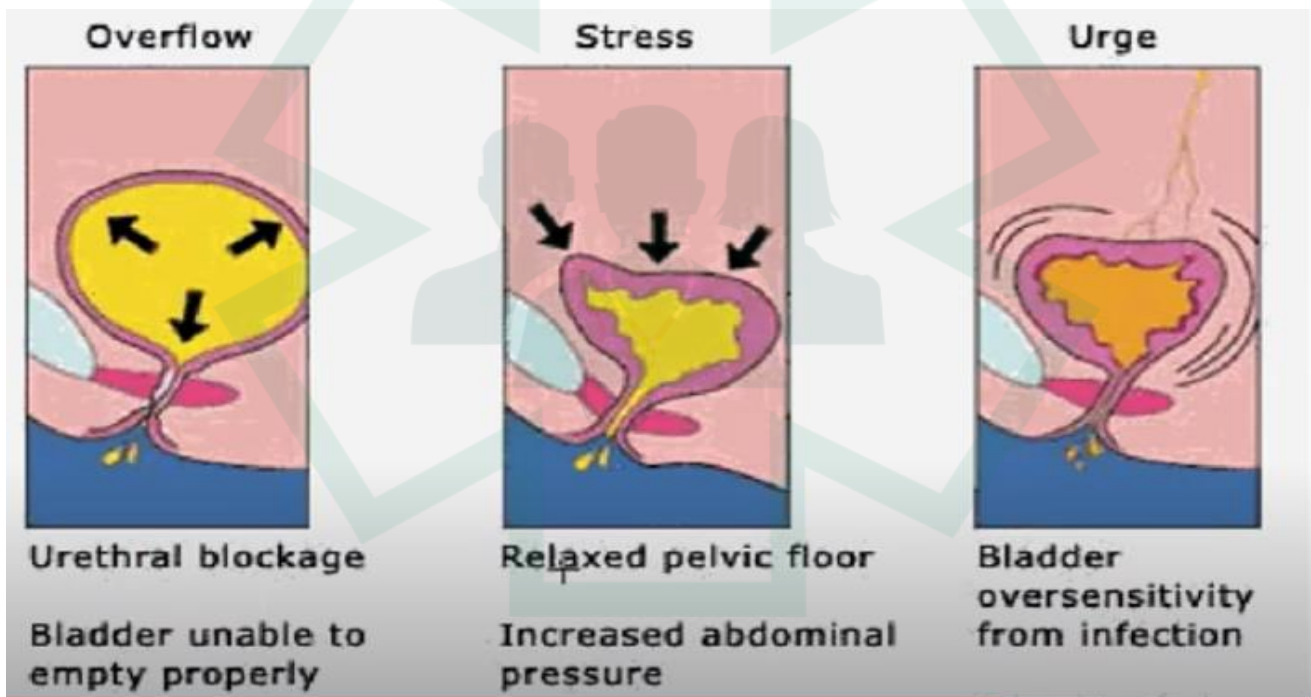
- C. Overflow incontinence
- D. Neurogenic bladder

**Answer < A:**Stress incontinence.

**Explanation:**

During coughing or straining, the intra-abdominal pressure increases, resulting in stress incontinence due to relaxed pelvic floor muscles.

Some common types of incontinence are depicted in the image below.



- 
12. A young patient presented with muscle spasms, numbness in hands and feet, seizures and difficulty in breathing due to laryngospasm.. His blood picture showed electrolyte imbalance. What is the cause for these manifestations in the patient.



- A. Respiratory Acidosis
- B. Respiratory Alkalosis
- C. Metabolic acidosis
- D. Metabolic Alkalosis

**Answer < B:**Respiratory Alkalosis

**Explanation:**

The given patient is suffering from tetany due to hypocalcemia. The levels of free and bound calcium are determined by :

- 1) Albumin
- 2) Blood pH levels

Alkalosis results in decreased H<sup>+</sup> ion concentration, resulting in more albumin binding to calcium. This causes reduced free calcium levels leading to hypocalcemia and tetany in this patient.

---

## Biochemistry

13. **A patient on a maize diet presented with diarrhea, dementia and dysentery . Which vitamin deficiency is responsible for the features**

- A. Niacin
- B. Thiamine
- C. Riboflavin
- D. Pyridoxine

**Answer < A:** Niacin

**Explanation:**

- Maize is low in Tryptophan which is an essential amino acid required for Niacin synthesis. This leads to Niacin deficiency in the population who have a diet majorly consisting of maize.
- Niacin Deficiency leads to pellagra which classically presents with diarrhoea , dementia and dysentery.

---

14. **A patient presented with dryness in eye with a gritty sensation along with corneal softening. What is the most probable cause ?**

- A. Vitamin A deficiency
- B. Riboflavin Deficiency
- C. Viral Keratitis
- D. Follicular conjunctivitis

**Answer < A:** Vitamin A deficiency

**Explanation:**

Xerophthalmia [Dryness of Eye] is the a common presenting feature of Vitamin A Deficiency along with Keratomalacia [Softening of Cornea]

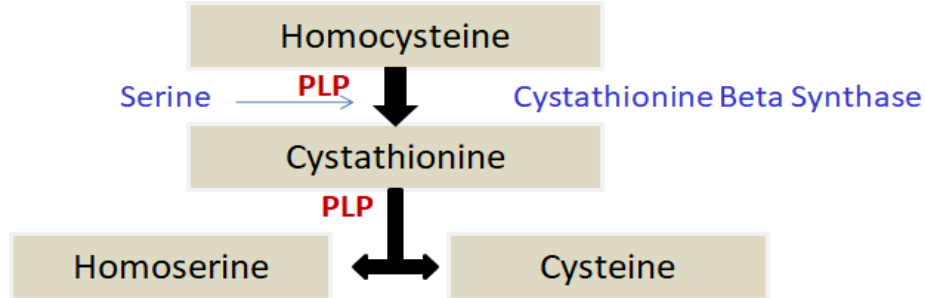
---

15. **Which amino acid needs to be supplemented through diet in patient with cystathionine beta synthase**

- A. Cysteine
- B. Methionine
- C. Serine
- D. Tryptophan

**Answer < A:** Cysteine

**Explanation:**



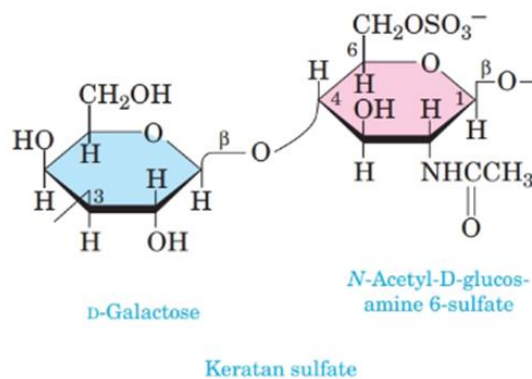
Since Cystathionine is broken down into Cysteine and Homoserine with the help of Cystathioninase.

The deficiency of Cystathionine beta synthase will lead to deficiency of cystathionine and hence cysteine cannot be formed and need to be supplemented in the diet.

**16. Corneal Transparency is maintained by which of the following GAGs**

- A. Keratan Sulphate
- B. Dermatan Sulphate
- C. Heparan Sulphate
- D. Chondroitin Sulphate

**Answer < A:** Keratan Sulphate



**Explanation:**

- Keratan Sulphate is made up of N Acetyl Glucosamine + Galactose
- It was first discovered in cornea [and responsible is corneal transparency]
- Also it is the only glycosaminoglycan without any acid sugar [Hence does not require uronic acid pathway]



17. Which of the following is associated with defect in mismatch repair

- A. Hereditary NPCC
- B. SCID
- C. Bloom Disorder
- D. MUTYH Associated Polyposis

Answer < A: Hereditary NPCC

Defects In DNA	Repair Mechanism	Disorders Associated
<ul style="list-style-type: none"> <li>•Double strand breaks</li> <li>•Single strand breaks</li> <li>•Intrastrand Cross links</li> </ul>	<p>Non-homologous End Joining (NHEJ)</p> <p>Homologous Recombination (HR)</p>	<ul style="list-style-type: none"> <li>•Severe combined Immunodeficiency disease (SCID)</li> <li>•Radio-sensitive Severe combined Immunodeficiency disease (RS-SCID)</li> <li>✓Werner's Syndrome</li> </ul>
<ul style="list-style-type: none"> <li>•Bulky Adducts</li> <li>•Pyrimidine Dimers</li> </ul>	Nucleotide Excision Repair (NER)	<ul style="list-style-type: none"> <li>✓Xeroderma Pigmentosa</li> <li>✓Cockayne Syndrome</li> <li>✓Trichothiodystrophy</li> </ul>
Abasic Sites	Base Excision Repair (BER)	MUTYH-associated Polyposis
Bases Mismatch	Mismatch Repair(MMR)	<ul style="list-style-type: none"> <li>✓Hereditary Non-Polyposis Colorectal Cancer (HNPCC)</li> <li>✓Lynch Syndrome</li> </ul>

18. A patient had dinner at 8 PM in the night and dose his blood sugar test at 7 AM in the morning. What is the major source of glucose

- A. Muscle Glycogen
- B. Liver Glycogen
- C. Gluconeogenesis
- D. Dietary Carbohydrate

**Answer < B:** Liver Glycogen

**: Source of Blood Glucose**

- Fed State [0-4 Hrs after Meal]- Dietary Carbohydrate
  - Fasting Stage I [4-16 Hrs Post Prandial]- Liver Glycogen [Note Muscle Glycogen never contributes to blood glucose]
  - Fasting Stage II /III /IV [16-48 Hrs Post Prandial]- Gluconeogenesis . Liver Glycogen exhausted after 16 hrs.
- 

19. A patient with tendon xanthomas , Increased LDL and cholesterol .  
What is the most probable diagnosis ?

- A. Type I Hyperlipoproteinemia
- B. Type II Hyperlipoproteinemia
- C. Type III Hyperlipoproteinemia
- D. Abetalipoproteinemia

**Answer < B:** Type II Hyperlipoproteinemia

	Lipoprotein Increased	Lipid Increased	Xanthomas
<b>Type I</b>	Chylomicron > VLDL	Triglycerides	Eruptive Xanthomas
<b>Type II</b>	LDL	Cholesterol	Tendenous Xanthomas
<b>Type III</b>	Chylomicron , VLDL , LDL	Triglycerides + Cholesterol	Palmar + Tuberoeruptive Xanthomas
<b>Type IV</b>	Chylomicron > VLDL	Triglycerides	Eruptive Xanthomas
<b>Type V</b>	Chylomicron > VLDL	Triglycerides	Eruptive Xanthomas

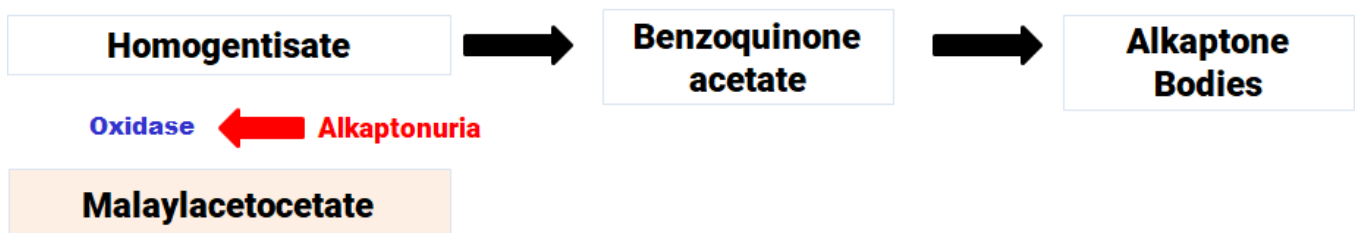
20. A 5 year old child was brought to the physician with a history of black urine . There is no history of fever or any other complaints. There is no growth retardation and all the developmental milestones are normal. The child is suspected to have an enzyme defect for metabolism of an aromatic amino acid. What is the enzyme deficient ?

- A. Homogentisate oxidase
- B. Homogentisate dehydrogenase
- C. Tryptophan Hydroxylase
- D. Tyrosine Transaminase

**Answer < A:** Homogentisate oxidase

**Explanation:**

Diagnosis - Alkaptonuria



- Autosomal Recessive Disorder
- Garrod's Tetrad [Alkaptonuria, Albinis, Pentosuria , Cystinuria]
- Normal Life till 3-4 Decade . Urine Darkening on standing is the only symptom in children
- Ochronosis [Adult]- Pigmentation d/t Alkaptone Bodies in I/V Disc, Cartilage of nose / ear
- Arthritis . There is No Intellectual Defect

---

## Pathology

21. A Patient presents to you with generalized weakness and easy fatigability. He gives you a history of working in a factory with an exposure to Benzene. Which of the following cases would you suspect in this patient

- A. Blood Cancer
- B. Urinary Bladder Cancer
- C. Carcinoma Gall Bladder
- D. Hepatocellular Carcinoma

**Answer < A:** Blood Cancer

### Explanation:

- Benzene causes harmful effects on the bone marrow and can cause a decrease in red blood cells, leading to anemia. It can also cause excessive bleeding and can affect the immune system, increasing the chance for infection.
- The Department of Health and Human Services (DHHS) has determined that benzene causes cancer in humans. Long-term exposure to high levels of benzene in the air can cause leukemia, cancer of the blood-forming organs.



22. **Chronic Alcoholic patient with history of increasing abdominal girth . On liver biopsy there are reddish inclusions . What are these made up of**

- A. Actin
- B. Microtubules
- C. Intermediate filaments
- D. Myofibril

**Answer < C:** Intermediate filaments

**Explanation:**

Accumulation of intermediate filaments in lung macrophages and endotheliocytes has been found in patients with chronic alcoholism and purulent destructive pulmonary diseases. Excess accumulation of cytoskeletal elements reflects cell dystrophy.

---

23. **All are increased in IDA except?**

- A. TIBC
- B. Soluble transferrin receptor
- C. Transferrin saturation
- D. Erythropoietin

**Answer < C:** Transferrin saturation

**Explanation:**

- High iron binding capacity and low transferrin saturation are suggestive of iron deficiency (even in the presence of a normal or elevated ferritin).

- Soluble transferrin receptor-Elevated in tissue iron deficiency
- 

24. **Woman on pap smear having disorganised growth of cells with hyperchromatic nuclei, which phenomenon is occurring here**

- A. Dysplasia
- B. Metaplasia
- C. Hypertrophy
- D. Carcinoma

**Answer < D:** Carcinoma

**Explanation:**

Differentiation: refers to the morphology of cells compared to normal cells of the same tissue. Well differentiated tumour cells look and function like normal cells of the tissue. Poorly differentiated tumour cells (anaplastic cells) do not function like the normal tissue and appear abnormal on microscopy. Anaplastic cells have the following features:

- **Pleomorphic:** continual variation in size and shape.
  - **Hyperchromatic:** cells are dark-staining with large nuclei.
  - **Loss of polarity:** normal cells are anchored and oriented to the basement membrane; anaplastic cells lose this uniform orientation and the tumour cells grow in a disorganized way.
  - **Mitoses:** increased proliferation results in abnormally large number of cells undergoing mitosis.
-

25. Poor prognostic marker in MM is-

- A. S. creatinine
- B. Hypercalcemia
- C. B2 microglobulins
- D. Telomerase

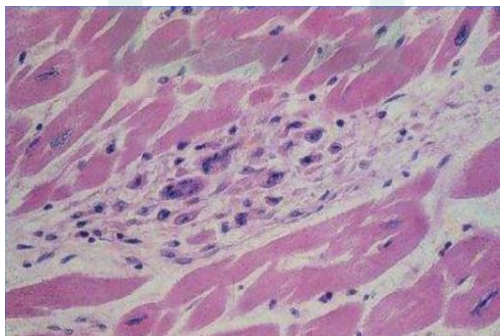
**Answer < C:** B2 microglobulins

**Explanation:**

Beta 2 microglobulin is a low molecular weight protein found on the surface of all nucleated cells: it is the light chain of the HL-A histocompatibility complex. The increased levels of serum beta 2 microglobulin in patients with multiple myeloma have been associated with a poor prognosis.

---

26. A 34 year old female presenting to the OPD with migratory arthritis and examination revealed a pan systolic murmur. ECHO was performed which is suggestive of mitral regurgitation. Biopsy image is provided. Diagnosis will be?



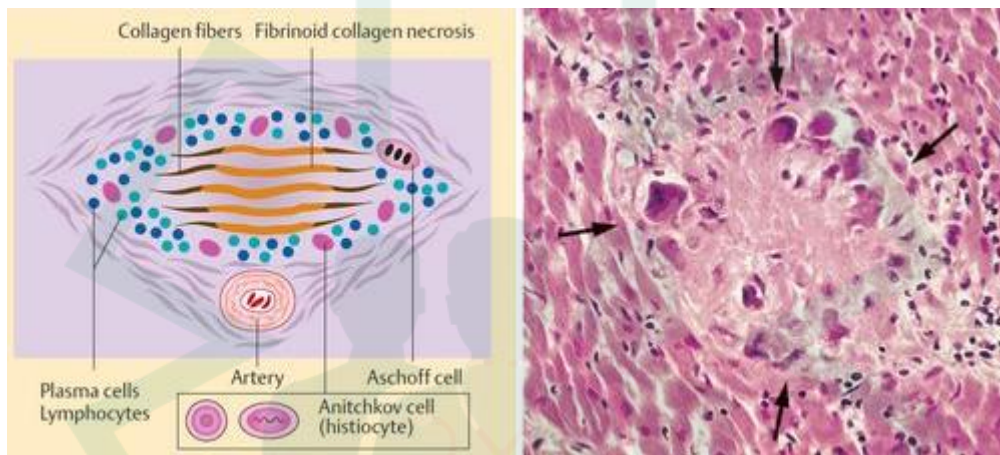
- A. Infective endocarditis
- B. Rheumatic heart disease
- C. SABE
- D. Cardiac failure

**Answer < B:** Rheumatic heart disease

**Explanation:**

An endomyocardial biopsy performed at cardiac catheterization demonstrated and Aschoff's body in the endocardium and thus confirmed a clinical suspicion of active carditis.

Aschoff bodies are nodules found in the hearts of individuals with rheumatic fever. They result from inflammation in the heart muscle and are characteristic of rheumatic heart disease.



A Little Help to Get Started

27. A 18 year old male presented to the OPD with gum bleeding, fever low TLC and low platelet count. General examination is unremarkable. Further investigation show a low reticulocyte count, absent megakaryocytes and no immature cells. Diagnosis will be?

- A. Aplastic anemia
- B. MDS
- C. PNH
- D. None

**Answer < A:** Aplastic anemia

**Explanation:**

Symptoms are due to the underproduction of red cells, white cells, & platelets. Symptoms may be severe from the start or gradually worsen over time as the disease progresses

Low red cell count can cause:

- Fatigue
- Pallor
- Rapid heart rate
- Shortness of breath with exercise
- Weakness
- Lightheadedness upon standing
- Leukopenia can cause increase risk of infection
- Thrombocytopenia can cause bleeding:- Bleeding gums, easy bruising, Nose bleeds, rash

**Blood test will show**

- Anaemia
- Leukopenia
- Low reticulocyte count
- Low platelet count

---

**28. HNPCC has defect in**

- A. Nucleotide excision
- B. Base pair excision
- C. Point mutation
- D. Mismatch repair gene

**Answer < D:** Mismatch repair gene

**Explanation:**

Hereditary nonpolyposis colorectal cancer (HNPCC) is a common inherited form of neoplasia caused by germline mutations in DNA mismatch repair (MMR) genes. MMR proteins have been reported to associate with several proteins, including the human exonuclease 1 (hEXO1).

---

**29. Patient with general fatigue and tiredness. Primary clinical examination is uneventful. Normal TLC, DLC. No immature cells seen. Superficial discrete lymphnodes enlarged. On biopsy effaced architecture, indented nucleus and prominent nucleolus containing atypical cells. CD 10 & BCL-2 positive.**

- A. Follicular
- B. Burkitts
- C. NHL
- D. Mycosis Fungoides

**Answer < A:** Follicular

**Explanation:**

The diagnosis of follicular lymphoma is confirmed by removing all or part of an enlarged lymph node to examine its cells under a microscope, a procedure known as a biopsy.

CD10 expression is present in cases of FL. Follicles demonstrated strong positivity. One CD10-positive case of FL showed equivocal staining for BCL2 and one an absence of staining for BCL2.

---

## Pharmacology

**30. What is the mechanism of action of Tocilizumab?**

- A. Inhibits binding of IL-1
- B. Inhibits binding of IL-6 to its receptor IL-6R
- C. TNF Alpha inhibition
- D. IL-18 inhibition

**Answer < B:** Inhibits binding of IL-6 to its receptor IL-6R

**Explanation:**

Tocilizumab is a novel monoclonal antibody that competitively inhibits the binding of interleukin-6 (IL-6) to its receptor (IL-6R). Inhibiting the entire receptor complex prevents IL-6 signal transduction to inflammatory mediators that summon B and T cells. Tocilizumab has a nonlinear pharmacokinetic profile. It may be beneficial for the treatment of RA in patients who do not respond to methotrexate or disease-modifying antirheumatic drugs.

---

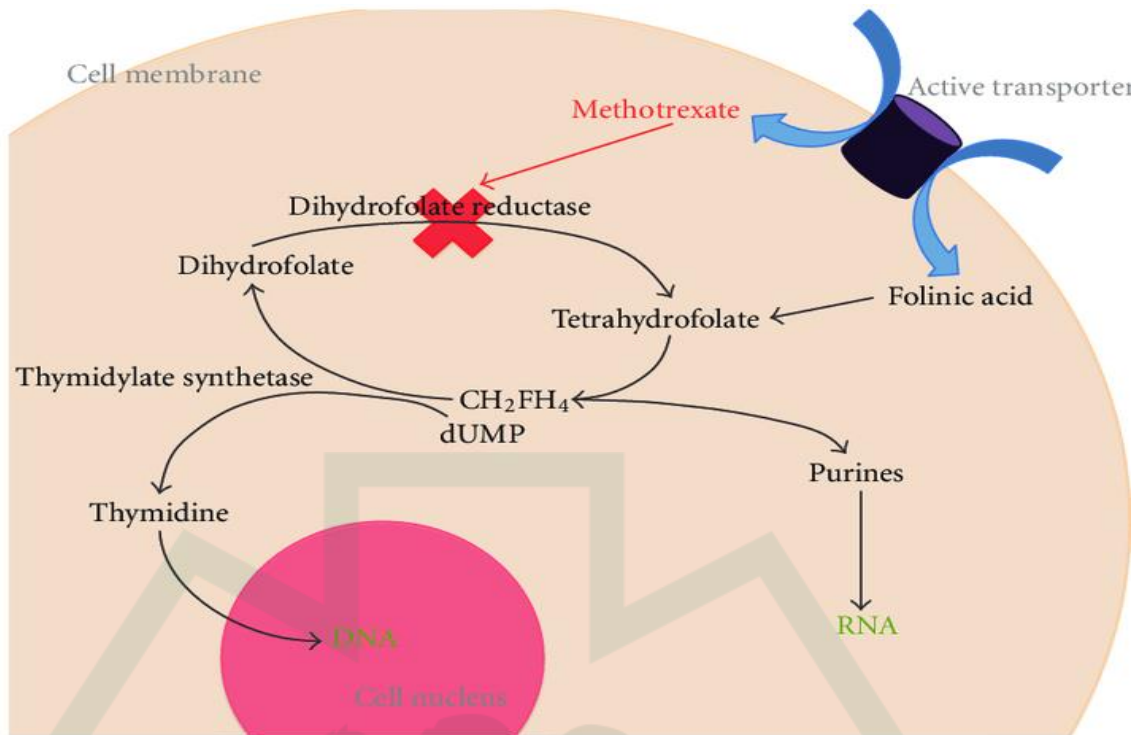
**31. What is the mechanism of action of Methotrexate**

- A. Inhibition of Dihydrofolate reductase
- B. Inhibits cell replication by acting on G phase of cell cycle
- C. Inhibits pyrimidine synthesis
- D. Inhibits Thymidylate synthase

**Answer < A:** Inhibition of Dihydrofolate reductase

**Explanation:**

Methotrexate inhibits dihydrofolate reductase, preventing the reduction of dihydrobiopterin (BH2) to tetrahydrobiopterin (BH4), leading to nitric oxide synthase uncoupling and increased sensitivity of T cells to apoptosis, thereby diminishing immune responses



32. Which antitubercular drug inhibits the action of OCPs?

- A. Rifampicin
- B. Ethambutol
- C. Isoniazid
- D. Pyrazinamide

**Answer < A:** Rifampicin

**Explanation:**

Rifampicin causes an increase in the rate of metabolism of OCPs, resulting in unacceptable rates of breakthrough bleeding and pregnancy. Rifampin, an inducer of enzymes that metabolizes estrogens, decreases the effectiveness of OCPs. Other drugs that cause a reduction in the efficacy of OCPs include anticonvulsants including carbamazepine, phenytoin, topiramate and selected



antibiotics like azithromycin , erythromycin, ketoconazole, penicillin (and derivatives), rifabutin , and tetracycline antibiotics

---

**33. A patient is on digoxin therapy with some concomitant medications. At presentation, the patient develops atrial fibrillation with control ventricular rate & his serum digoxin raised from his previous value. Which of the following medication have enhanced digoxin toxicity?**

- A. Atenolol
- B. Clarithromycin
- C. KCL
- D. Triamterene

**Answer < B:** Clarithromycin

**Explanation:**

- Atrial fibrillation along with AV Node block is the characteristic arrhythmia observed in Digoxin toxicity. The serum digoxin level must not be more than 2.0ng/ml.
  - Digoxin inhibits Na+K+ATPase pump by binding to the potassium binding site on the myocardial cell. This in turn leads to increased intracellular Ca leading to increased inotropic effects. In cases of hypokalemia in blood, more digoxin binds to the myocardium and precipitates digoxin toxicity. Loop and thiazide diuretics produce hypokalemia. RAAS inhibitors cause hyperkalemia. Beta blockers decrease renin release and produce hyperkalemia. Potassium sparing diuretics inhibit the action of aldosterone.
  - P-glycoprotein inhibitors like clarithromycin increase the digoxin toxicity.
- 

**34. A patient is taking metronidazole for anaerobic infection. Which of the following should be avoided during this period.**

- A. Alcohol
- B. Ciprofloxacin

- C. Rifampicin
- D. Colchicine

**Answer < A:** Alcohol

**Explanation:**

Consumption of alcohol while taking metronidazole results in disulfiram like reaction in the body. The patient experiences headaches, stomach cramps, nausea, vomiting, and flushing (warmth, redness, or tingly feeling).

---

**35. Topiramate is used in the treatment of**

- A. Migraine
- B. LGS
- C. ADHD
- D. Dementia

**Answer < A:** Migraine

**Explanation:**

The recommended dosage of topiramate for migraine prevention is 50 mg twice per day. Patients should start with 25 mg once per day, then increase by 25 mg per week up to the recommended dosage. Topiramate is a neuromodulatory compound with neuron stabilizing properties and is approved for the preventive treatment of migraine.

---

**36. Which of the following drugs is used for the long term management of obesity?**

- A. Sibutramine
- B. Fenfluramine
- C. Metformin

D. Liraglutide

**Answer < D:** Liraglutide

**Explanation:**

Liraglutide acts as a GLP-1 agonist and helps in long term management of obesity. Fenfluramine and Sibutramine are banned due to their increased cardiovascular toxicity. Bupropion in combination with naltrexone or zonisamide is also used for the management of obesity.

---

## Forensic

37. A child accidentally ingested some fruit which he plucked from a tree while playing . After the ingestion of the fruit , he presented with restlessness, painful swallowing, photophobia, dry skin , urinary retention and elevated body temperature. What is the possible poisoning and the appropriate antidote for it?

- A. Datura & Physostigmine
- B. Yellow oleander & Physostigmine
- C. Datura & Pralidoxime
- D. Yellow oleander & Pralidoxime

**Answer < A:** Datura & Physostigmine

**Explanation:**

This is a case of datura poisoning showing the manifestations of excess atropine levels.. The antidote of choice is physostigmine as neostigmine does not cross the blood brain barrier. Physostigmine acts as anticholinesterase and increases the levels of acetylcholine in the neuromuscular junction.

---

38. A 30 year old male presents with a history of consumption of some unknown substance. The attending doctor notices the person to be having diaphoresis, headache and acute coronary spasm like features. The person is least likely to show which clinical feature?

- A. Bradycardia
- B. Tachycardia
- C. Hyperthermia
- D. Hypertension

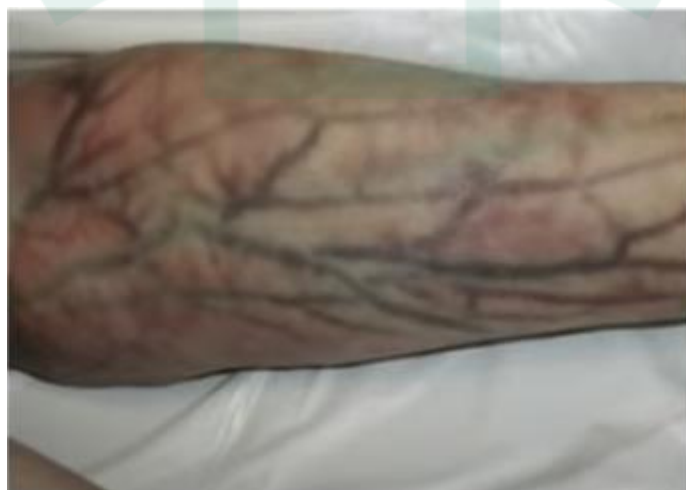**Answer < A:** Bradycardia.

**Explanation:**

This is a case of cocaine overdose. Cocaine is predominantly a vasoconstrictor. It leads to an increase in the heart rate. Respiratory rate and blood pressure. It also causes a rise in the body temperature, known as 'Cocaine Fever'.

---

39. A doctor at autopsy noticed the following finding on a cadaver. Which of the following is true regarding this finding?



- A. It is due to sulphaemoglobin pigment
- B. This change is seen at 24 hours

- C. It is non bacterial
- D. It is associated with lightning case

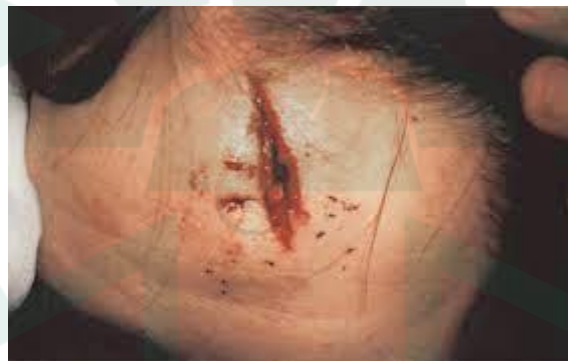**Answer < A:** It is due to sulphaemoglobin pigment

**Explanation:**

The finding in the above image is Marbling. This change starts at about 24hours after death. It becomes visible to the naked eye at 36-48 hours after death. It is due to sulphaemoglobin pigment.

---

**40. Identify the injury**



- A) Incised looking laceration
- B) Laceration
- C) Laceration looking incision
- D) Incision

**Answer < A:** Incised looking laceration

**Explanation:**

The given wound is seen on the forehead of the patient. Although the margins are irregular, it is an incised looking lacerated wound due to the sheering forces on the skin. Such wounds can also be seen on shin area.

---

**41. While recording evidence in the court of law, lawyer asked the witness, “Were you present when A killed B?”, and the witness answered “yes”. This type of questioning is permitted in?**

- A. Examination in chief
- B. Direct examination
- C. Redirect examination
- D. Cross examination

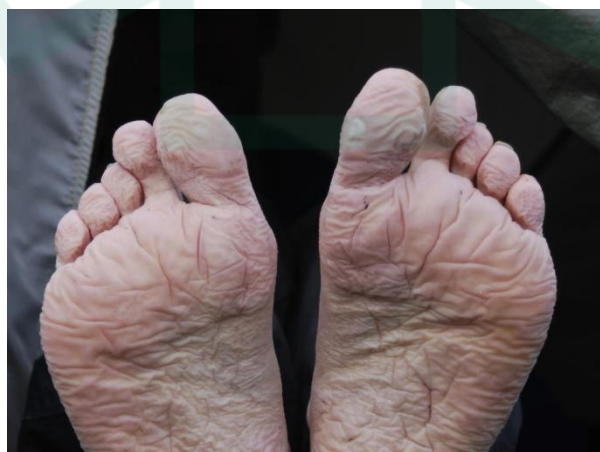**Answer < D:** Cross examination.

**Explanation:**

this is a type of leading question and it is permitted in cross examination.

---

**42. A dead body was recovered from near a pond by the police. During autopsy, the following finding was observed. The below phenomenon is due to**



- A. Case of torture in hot water
- B. Case of postmortem hanging
- C. Case of immersion in water for 36 hours

D. Case of colliquative liquefaction

**Answer < C:** Case of immersion in water for 36 hours

**Explanation:**

this is a case of immersion in water for more than 36hrs which is characterized by mottling and greenish black discolouration of the skin due to putrefactive changes.

---

**43. A woman gave birth to twins. However, her husband asked for a DNA fingerprinting test as he believed that the babies did not belong to him. The results showed that one baby did not belong to him. This is a case of:**

- A. Superfecundation
- B. Superfetation
- C. Atavism
- D. Posthumus child

**Answer < A:** Superfecundation

**Explanation:**

Superfecundation- two different acts of coitus leading to foetus formation. It can be with two different males.

Actual twins occur due to single act of coitus

Superfoetation- conceiving to foetuses in two different cycles of mensruation

---

**44. A man was sitting in the balcony which was overlooking a park. He was sitting naked for sexual gratification. This is called**

- A. Voyeurism
- B. Masochism
- C. Exhibitionism
- D. Fetishism

**Answer < C:** Exhibitionism

**Explanation:**

Exhibitionism- display of private parts in public. It is punishable under section 294 IPC.

Masochism- Giving pain to others

Fetishism-Sexual gratification is obtained from inanimate objects belonging to the opposite gender.

Stalking- Following a female physically or digitally, inspite of clear prior disinterest showed by the female.

---

**45. A daily wage labourer was working in the farm on a hot summer day and suddenly collapsed. He was brought to the hospital and the attending doctor measured his body temperature as 106 degrees fahrenheit. Which of the following symptoms is least likely to be seen?**

- A. Sweating
- B. Hot skin
- C. Hypotension
- D. Disorientation

**Answer < A:** Sweating

**Explanation:**

The given person is doing muscular activity in hot weather conditions. His body temperature is 40.5 degrees centigrade. These conditions result in heat stroke. At this temperature, the hypothalamus ceases to function causing an absence of sweating.

---

**46. Identify the active principle in the poisonous seed shown below**





- A. Abrin
- B. Ricin
- C. Cannabinol
- D. Bhilawanol

**Answer < D:** Bhilawanol

**Explanation:**

The nut shown in the image is Marking Nut or Semecarpus Anacardium. It is also known as Bhilawa. The two active principles in this are Bhilawanol and Semi Carpool

---

## Microbiology

47. A child admitted with fever, rash begins behind ears, conjunctivitis, coryza, cough and koplik spot. Based on the clinical manifestations, choose the correct description of the pathogen?

- A. SS enveloped RNA virus
- B. DS enveloped RNA virus
- C. SS naked RNA virus

D. DS naked RNA virus

**Answer < A:** SS enveloped RNA virus

- The pathogen causing Measles is paramyxovirus.
- The tubelike, helically symmetrical nucleocapsid contains a monopartite, single-stranded, negative-sense RNA genome and an RNA-directed RNA polymerase. The nucleocapsid associates with the matrix protein (M) at the base of a double-layered lipid envelope.

---

**48. Name the parasite whose microfilariae have a sheath with no nuclei at the tail end.**

- A. Wuchereria Bancrofti
- B. Brugia malayi
- C. Loa loa
- D. None

**Answer < A:** Wuchereria Bancrofti

- Wuchereria bancrofti is a filarial (arthropod-borne) nematode (roundworm) that is the major cause of lymphatic filariasis.
- It has a short cephalic or head region connected to the main body by a short neck, which appears as a constriction. Dark spots are dispersed nuclei throughout the body cavity, with no nuclei at the tail tip.
- The tip of the tail has 15 pairs of minute caudal papillae, the sensory organs.

---

**49. History of Pastry intake causing food poisoning. What is the causative agent**

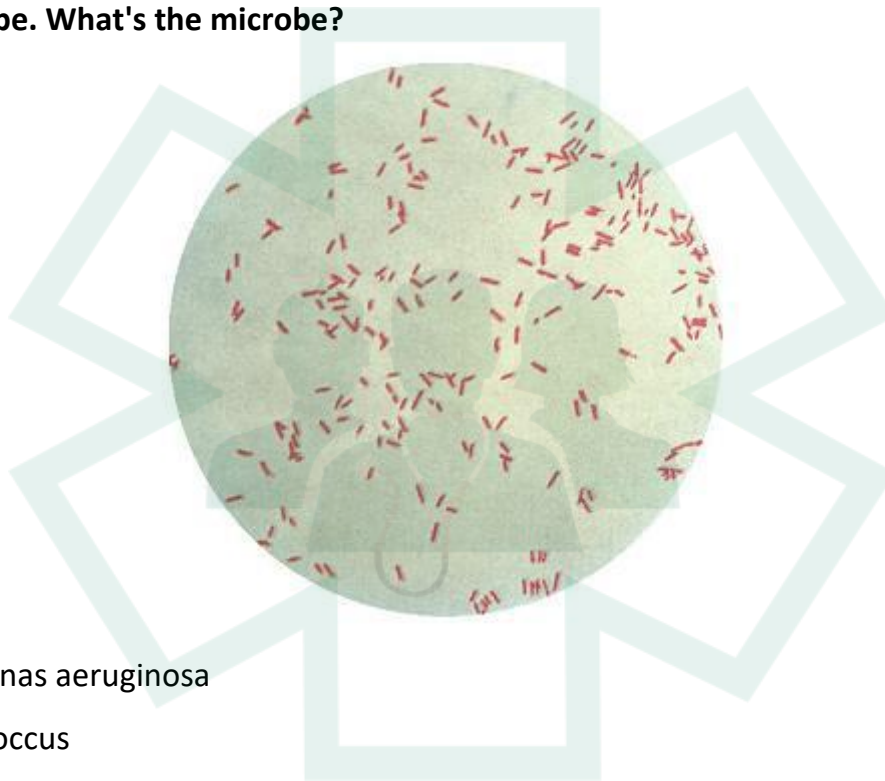
- A. S aureus
- B. B. cereus
- C. EIEC
- D. Verotoxin E.coli

**Answer < A:** S aureus

Staphylococcal food poisoning (SFP) is one of the most common food-borne diseases and results from the ingestion of staphylococcal enterotoxins (SEs) preformed in food by enterotoxigenic strains of *Staphylococcus aureus*.

---

**50. A patient presented with 70% burns. A test was done on a sample collected from the burnt site as shown in the picture in suspicion of the probable causative organism which is an obligate aerobe. What's the microbe?**



- A. *Pseudomonas aeruginosa*
- B. Meningococcus
- C. *Streptococcus pyogenes*
- D. Pneumococcus

**Answer < A:** *Pseudomonas aeruginosa*

**Explanation:**

Invasive burn wound sepsis with *Pseudomonas aeruginosa* is a major concern in burn patient care settings. *PSEUDOMONAS AERUGINOSA* (*Bacillus pyocyaneus*) is normally an organism of low invasiveness and virulence, frequently noted as a local inhabitant of burns, surgical wounds and

the genitourinary tract. Under suitable host conditions, however, this gram-negative, motile rod can assume the role of a life-threatening pathogen

---

**51. A truck driver presented with a painless, demarcated ulcer on penis with inguinal lymphadenopathy. What is the best method of visualization of motility of the probable causative agent?**

- A. Dark field microscopy
- B. Light microscopy
- C. Fluorescent microscopy
- D. Electron microscopy

**Answer < A:** Dark field microscopy

**Explanation**

- The patient has developed syphilis.
  - Direct detection methods for *Treponema pallidum* include dark-field microscopy (DFM), direct fluorescence antibody (DFA) testing, immunohistochemistry (IHC), and nucleic acid amplification tests (NAATs).
- 

**52. Swab is discarded in which color bin?**

- A. Yellow bag
- B. Red bag
- C. White bag
- D. Blue bag

**Answer < A:** Yellow bag

**Explanation**

**Yellow Bin :**

- Human Anatomical Waste, Animal Anatomical Waste,
- Items contaminated with blood, body fluids like dressings, plaster casts, cotton swabs and bags containing residual or discarded blood and blood components.
- Discarded linen, mattresses, beddings contaminated with blood or body fluid, routine mask & gown.
- Pharmaceutical waste like antibiotics, cytotoxic drugs including all items contaminated with cytotoxic drugs along with glass or plastic ampoules, vials etc.
- Liquid waste generated due to use of chemicals in production of biological and used or discarded disinfectants, Silver X - ray film developing liquid, discarded Formalin, infected secretions, aspirated body fluids, liquid from laboratories and floor washings, cleaning, house - keeping and disinfecting activities etc
- Blood bags, Laboratory cultures, stocks or specimens of microorganisms, live or attenuated vaccines, human and animal cell cultures used in research, production of biological, residual toxins, dishes and devices used for cultures

**Red bin :**

- Wastes generated from disposable items such as tubing, bottles, intravenous tubes and sets, catheters, urine bags, syringes without needles, fixed needle syringes with their needles cut, vacutainers and gloves.

**WHITE Bin :**

- Waste Sharps including metals Needles, syringes with fixed needles, needles from needle tip cutter or burner, scalpels, blades, or any other contaminated sharp object that may cause puncture and cuts. This includes both used, discarded and contaminated metal sharps

**Blue bin :**

- Broken or discarded and contaminated glass including medicine vials and ampoules except those contaminated with cytotoxic wastes.

**53. A female engineer works for 12- 14 hours a day and gives a history of consuming only fast food. There are no vegetables or fruits in his diet. Her Hb count is 9gm/dl MCV 120 fl. On examination, PS shows macrocytes. What will be the diagnosis?**

- A. Vitamin B12 deficiency
- B. Folic acid deficiency
- C. Vitamin D deficiency
- D. None

**Answer < A:** Vitamin B12 deficiency

The patient has vitamin B12 deficiency as there is lack of dietary intake.

Dietary Insufficiency: Vitamin B12 is stored in excess in the liver; however, patients who have followed a strict vegan diet for approximately three years may develop a B12 deficiency from a lack of dietary intake.

---

**54. A patient was suspected of having brucellosis. Serum sample was sent for a standard agglutination test. It came negative initially but after dilution of the serum sample, the test was positive. What could be the reason for the initial negative test?**

- A. Prozone
- B. Postzone
- C. Complement inactivation
- D. Antigen antibody complexes

**Answer < A:**Prozone

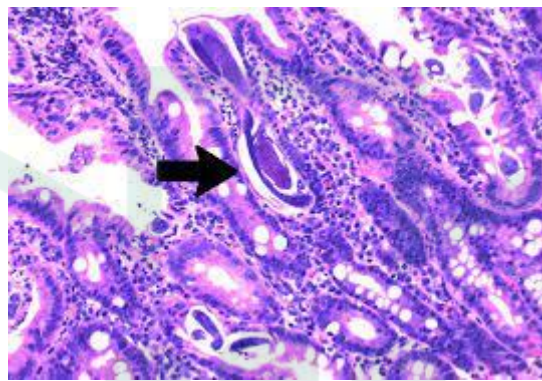
**Explanation:**

Prozone is a zone of excess antibodies. The immune complexes formed in this zone are smaller in size making them difficult to be detected. Standard Agglutination Test is used to detect IgG, IgA and IgM antibodies. The sample is incubated at 37 degrees celsius for 48 hrs. A titre of 1:160 or

more is considered significant. False negative SAT is seen in prozone phenomenon and in the presence of incomplete antibodies or blocking antibodies.

---

55. A patient who was on steroids presented with nocturnal cough and chronic urticaria. BAL stain was done. Identify the organism.



- A. Strongyloides stercoralis
- B. Enterobius
- C. Ancylostoma
- D. Capillaria philippinensis

**Answer < A:** Strongyloides stercoralis

**Explanation:**

The question states that the patient has been using steroids, indicating that he is immunocompromised. Strongyloides stercoralis is known to cause severe infection in immunocompromised patients, known as Disseminated Strongyloidiasis. It is characterised by the presence of the larvae of this organism in various organs of the body.

---

56. **Blood spill management**

- A. Ethyl Alcohol

- B. Chlorhexidine
- C. Formaldehyde
- D. Sodium Hypochlorite

**Answer < D:** Sodium Hypochlorite

**Explanation:**

Saturate the area again with sodium hypochlorite 0.5% (10 000 ppm available chlorine). This is a 1:10 dilution of 5.25% sodium hypochlorite bleach, which should be prepared daily.

---

**57. A child presented with bloody stools and abdominal pain. What enrichment medium should be used for the faeces sample?**

- A. Selenite F broth
- B. Alkaline peptone water
- C. Blood agar
- D. Muller Hinton Broth

**Answer < A:** Selenite F broth

**Explanation:**

The given scenario suggests that the child most probably is suffering from Shigellosis. Selenite F Broth is used for the culture of Shigella.

---

**58. What is the vector for a parasite which has kinetoplast in one of its morphological forms?**

- A. Sand fly
- B. TseTse fly



- C. Female Anopheles Mosquito
- D. Triatomine bug

**Answer < A:** Sand fly

**Explanation:**

Kinetoplast is the organelle that helps in the motility of the amastigote form in leishmania donovani. The vector is sandfly. Tse tse fly is vector for sleeping sickness. Female anopheles mosquito is vector for malaria and reduvid bug is for Chaga's disease.

---

**59. A known case of AIDS with productive cough and fever was found to have consolidation in the right infrascapular area. X-Ray chest showed right lower lobe consolidation with CD4 count of 55 per microlitre. What is the most common cause of this?**

- A. Staphylococcus aureus
- B. Streptococcus pneumoniae
- C. Mycoplasma
- D. Pneumocystis jirovecii

**Answer < B:** Streptococcus pneumoniae

**Explanation:**

Persons with HIV-1 infection are more susceptible to bacterial infections because of defects in both cell-mediated and humoral immunity. HIV-1 seropositive individuals are particularly susceptible to infections with encapsulated bacteria, such as *Streptococcus pneumoniae*. Infection caused by the bacterium *Streptococcus pneumoniae*, which is spread through contact with respiratory droplets from a person who is carrying the bacteria. The bacteria are a major cause of common illnesses, such as inflammation of the sinuses (sinusitis), but can also result in life-threatening infections, including meningitis and pneumonia. People with weakened immune

systems, including people with HIV, are at higher risk for bacterial pneumonia, including *Streptococcus pneumoniae* infection, than people with healthy immune systems.

---

## PSM

60. Following admission of a RTA case, there is a spillage of blood on the hospital floor. Which disinfectant will you use to clean the floor

- A. Sodium Hypochlorite
- B. Ethyl alcohol
- C. Formaldehyde
- D. Chlorhexidine

**Answer < A: Sodium Hypochlorite**

**Explanation:**

Wipe the area with water and detergent until it is visibly clean. Saturate the area again with sodium hypochlorite 0.5% (10 000 ppm available chlorine). This is a 1:10 dilution of 5.25% sodium hypochlorite bleach, which should be prepared daily.

---

61. There is an outbreak of buboes in a community . What is the vector

- A. Xenopsylla [Rat Flea]
- B. Tse tse fly
- C. Human flea
- D. Sand fly

**Answer < A: Xenopsylla [Rat Flea]**

**Explanation:**

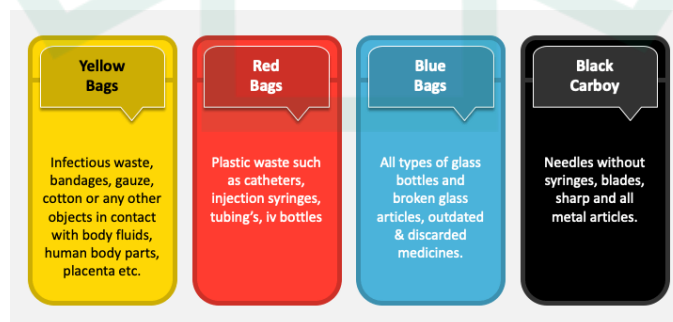
- While rats are the preferred host of *Xenopsylla cheopis*, while facing starvation this flea will feed off of almost any mammal.
- If infected rat fleas begin biting human, most of whom do not have resistance to plague, the disease can reach epidemic levels. In that instance individuals usually dies within 5 days from the first onset of symptoms, in some cases overnight. The human immune system is typically overwhelmed by *Yersinia pestis* which reproduces wildly within the victims bloodstream. But if it responds quickly enough, survival is possible.

62. A 11 year old girl is having symptoms of fever and sore throat and to diagnose throat swab was taken. Which bag is used to discard the swab after culture

- A. Yellow bag
- B. Red bag
- C. Blue bag
- D. White bag

**Answer < A: yellow bag**

**Explanation:**



63. **Global Hunger index does not include**

- A. Under 5 mortality rate

- B. IMR
- C. Child mortality rate
- D. Child undernutrition

**Answer < B IMR**

**Explanation:**

- The Global Hunger Index (GHI) is a tool that measures and tracks hunger globally as well as by region and by country. The GHI is calculated annually, and its results appear in a report issued in October each year.
- The Global Hunger Index measures hunger on a 100-point scale, with 0 being the best score (no hunger) and 100 being the worst, although neither of these extremes is reached in practice. The severity of hunger associated with the range of possible GHI scores is as follows:

Level	Value
Low	9.9
Moderate	10.0-19.9
Serious	20.0-34.9
Alarming	35.0-49.9
Extremely alarming	

**The GHI combines 4 component indicators:**

- 1) the proportion of the undernourished as a percentage of the population;

- 2) the proportion of children under the age of five suffering from wasting, a sign of acute undernutrition;
  - 3) the proportion of children under the age of five suffering from stunting, a sign of chronic undernutrition; and
  - 4) the mortality rate of children under the age of five.
- 

**64. A child presented with bluish white spots in the mouth followed by a rash. What is the genome of probable diagnosis?**

- A. Enveloped virus with single stranded RNA
- B. Naked virus with single stranded RNA
- C. Double stranded Naked RNA
- D. Double stranded Enveloped RNA

**Answer < A: Enveloped virus with single stranded RNA**

**Explanation:**

1. Measles is a childhood infection caused by a virus.
2. Measles signs and symptoms appear around 10 to 14 days after exposure to the virus. Signs and symptoms of measles typically include:
  - Fever
  - Dry cough
  - Runny nose
  - Sore throat
  - Inflamed eyes (conjunctivitis)
  - Tiny white spots with bluish-white centers on a red background found inside the mouth on the inner lining of the cheek — also called Koplik's spots
  - A skin rash made up of large, flat blotches that often flow into one another

Measles morbillivirus (MeV), also called measles virus (MV), is a single-stranded, negative-sense, enveloped, non-segmented RNA virus of the genus Morbillivirus within the family Paramyxoviridae. It is the cause of measles. Humans are the natural hosts of the virus; no animal reservoirs are known to exist.

---

65. **16 month old child, 8kg weight. On assessing in a growth chart, child falls between standard & -2sd. What should be done next for the management.**

- A. Assure mother that no malnutrition
- B. Mild malnutrition- home treatment
- C. Moderate malnutrition-teach mother on how to feed
- D. Severe malnutrition: refer to NRC

**Answer < D: Severe malnutrition: refer to NRC**

**Explanation:**

Nutrition Rehabilitation Center (NRC) is in a health facility where children with Severe Acute Malnutrition (SAM) are admitted and managed. A steady linkage with ICDS identifies and refers severely malnourished children in the community using MUAC tape.

---

66. **An anganwadi teacher takes weight & height of a 4 yr old & finds out that height for age <- 2SD, likely cause is**

- A. Chronic malnutrition
- B. Acute malnutrition
- C. Recent malnutrition
- D. No malnutrition

**Answer < A: Chronic malnutrition**

**Explanation:**

Chronic malnutrition is defined as a form of growth failure that causes both physical and cognitive delays in growth and development.

**World Health Organization (WHO) classification of nutritional status of infants and children**

<b>Nutritional status</b>	Age: birth to 5 years  Indicator and cut-off value compared to the median of the <i>WHO child growth standards</i> <u>a</u>
<b>Obese</b>	Weight-for-length/height <sub>b</sub> or BMI-for-age >3 standard deviations (SD) of the median
<b>Overweight</b>	Weight-for-length/height <sub>b</sub> or BMI-for-age >2 SD and ≤3 SD of the median
<b>Moderately underweight</b>	Weight-for-age <-2 SD and ≥-3 SD of the median
<b>Severely underweight</b>	Weight-for-age <-3 SD of the median
<b>Moderate acute malnutrition</b>	Weight-for-length/height <sub>b</sub> or BMI-for-age ≤-2 SD and ≥-3 SD of the median, or mid-upper arm circumference ≥115 mm and <125 mm
<b>Severe acute malnutrition</b>	Weight-for-length/height <sub>b</sub> or BMI-for-age <- 3 SD of the median or mid-upper arm circumference <115 mm, or bilateral pitting oedema
<b>Moderately stunted (moderate chronic malnutrition)</b>	Length/height-for-age <sub>b</sub> ≤-2 SD and ≥-3 SD of the median

<b>Severely stunted (severe chronic malnutrition)</b>	Length/height-for-age $\leq -3$ SD of the median
<b>Moderately wasted</b>	Weight-for-length/height $\leq -2$ SD and $\geq -3$ SD of the median
<b>Severely wasted</b>	Weight-for-length/height $< -3$ SD of the median

---

67. A farmer is having % skin rash which increase on sun exposure. There is also redness of tongue. Maize in his staple diet. Which of the following vitamin deficiency can cause this type of feature

- A. Niacin deficiency
- B. Folic acid deficiency
- C. Vit C deficiency
- D. Vit K deficiency

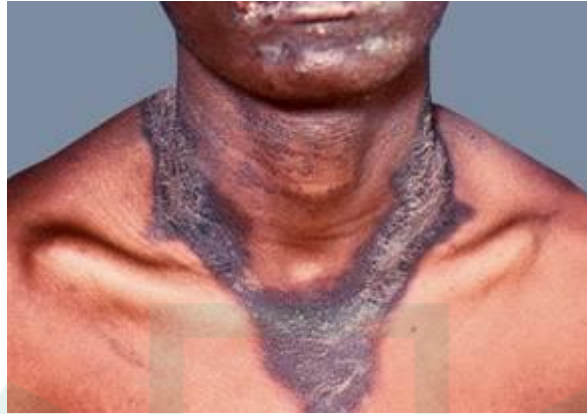**Answer < A: Niacin deficiency**

**Explanation:**

min B3) deficiency results in a condition known as pellagra. Pellagra includes the triad of dermatitis, dementia, and diarrhea and can result in death. Niacin deficiency can occur through genetic disorders, malabsorptive conditions, and interaction with certain medications. Pellagra is common in poor parts of the world, such as Africa and India, where corn (or maize) is a staple food. This is because corn is a poor source of tryptophan and niacin. In the United States, pellagra was prevalent in the early 1900's in the South where corn played a large role in the diet.



68. A 45 year old man presents with following skin changes. What relevant history will you take to diagnose this condition?



- A. H/o dietary pattern, dementia, diarrhea
- B. Dietary history
- C. Dementia
- D. Depression

**Answer < A: H/o dietary pattern, dementia, diarrhea**

**Explanation:**

Niacin (vitamin B3) deficiency results in a condition known as pellagra. Pellagra includes the triad of dermatitis, dementia, and diarrhea and can result in death. Niacin deficiency can occur through genetic disorders, malabsorptive conditions, and interaction with certain medications.

69. A girl child has had recurrent yeast & respiratory virus infection since she was 3 months old. Now considering studies for immune status, which vaccine is contraindicated?

- A. TT/Td
- B. Measles/MMR
- C. DPT
- D. Killed IPV

**Answer < B: Measles/MMR**

**Explanation:**

Contraindications for MMR vaccination include history of a severe (anaphylactic) reaction to a previous dose or to any component of the vaccine (such as gelatin or neomycin), pregnancy and immunosuppression.

---

70. In a 10 year school child under school health program, which vaccine has to be given?

- A. BCG
- B. MMR
- C. TT,Td
- D. DPT

**Answer < C: TT,Td**

**Explanation:**

Because immunity to tetanus decreases as one ages, older children need a Tdap vaccine that has a full dose of tetanus but contains a lower dose of diphtheria and pertussis. Once children are in their preteens, they should get a Tdap vaccine during their regular annual checkups until they reach 18 years of age.

---

71. **There is an outbreak of encephalitis in a community. According to the universal immunization schedule, the route of administration of vaccine for the likely infection is ?**

- A. Live & subcutaneous
- B. Killed & subcutaneous
- C. Live & intramuscular
- D. Killed & intramuscular

**Answer < A: Live & subcutaneous**

**Explanation:**

**Currently, there are three types of JE vaccines in use:**

1. The mouse brain-derived inactivated (Killed) vaccine.
2. The cell culture-derived inactivated (Killed) vaccine.
3. The cell culture-derived live, attenuated vaccine using SA 14-14-2 strain of JE virus.

Under the National program, the live attenuated (SA 14-14-2), cell culture-derived vaccine is used in India. It is presently manufactured in P. R. China. It is imported from there for use in India.

- Identification features: The bottle contains milky white caked powder. The label mentions that the vaccine is manufactured in China.
- Type of vaccine: Live
- Route of administration: Subcutaneous
- Dose: 0.5 mL
- Site: Left upper arm
- Whether part of NIS? - Included in the immunization schedule of select 83 JE endemic districts of Indian states
- Schedule under NIS: Two doses of JE vaccine are administered in all JE endemic districts of the country.
- The first dose is given at the age of 9–12 months along with the first dose of measles vaccine and the second dose is given at the age of 16 – 24 months along with DPT and OPV booster dose and measles second dose.

- Diluent: Sterile phosphate buffered saline (PBS). The diluent supplied along with the vaccine by the manufacturer ONLY should be used.
  - Strain of JE virus used: Live, attenuated SA 14-14-2 strain of JE virus
  - Storage: +2°C to +8°C
- 

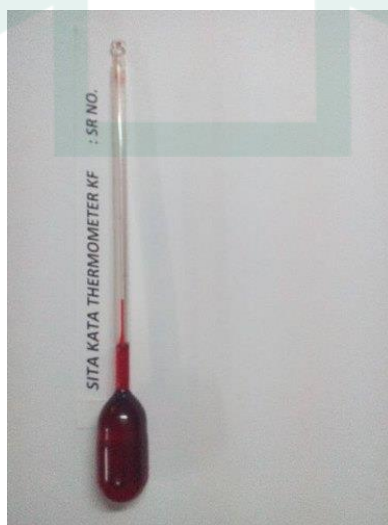72. **Low air velocity will be measured by**

- A. Kata thermometer
- B. Globe thermometer
- C. Wet thermometer
- D. Beckmans thermometer

**Answer < A: Kata thermometer**

**Explanation:**

The kata thermometer is a heated-alcohol thermometer; the time it takes to cool is measured and used to determine air current. It is useful for measuring low speeds in studies of air circulation.

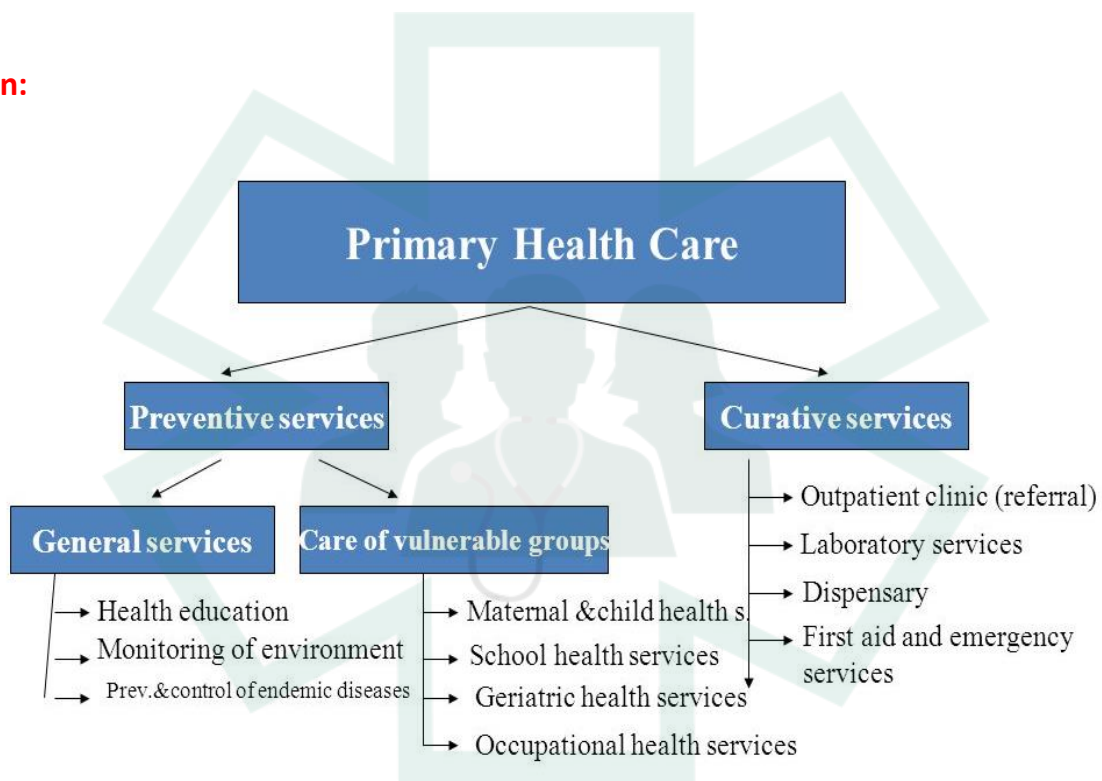


73. School health service is at which level

- A. District
- B. Subcentre
- C. Subdistrict
- D. PHC

Answer < D: PHC

Explanation:



74. Post diwali air pollution index chart was created. Air quality index values on 4 different days were plotted, A AQI value of 470 indicates which level air pollution

- A. Poor
- B. Very poor
- C. Severe
- D. Moderate

Answer < C: severe

Explanation:

Air Quality Index Levels of Health Concern	Numerical Value	Meaning
Good	0 to 50	Air quality is considered satisfactory, and air pollution poses little or no risk
Moderate	51 to 100	Air quality is acceptable; however, for some pollutants there may be a moderate health concern for a very small number of people who are unusually sensitive to air pollution.
Unhealthy for Sensitive Groups	101 to 150	Members of sensitive groups may experience health effects. The general public is not likely to be affected.
Unhealthy	151 to 200	Everyone may begin to experience health effects; members of sensitive groups may experience more serious health effects.
Very Unhealthy	201 to 300	Health warnings of emergency conditions. The entire population is more likely to be affected.
Hazardous	301 to 500	Health alert: everyone may experience more serious health effects

75. A researcher wants to know whether there is an association of CRP values with risk of MI/Cancer. They started to take CRP readings. 4 Values of RR was plotted (0.5, 1.5,1.7,1.8) with respect to CRP

- A. CRP increase disease/cancer risk
- B. CRP has no relationship
- C. CRP decreases & disease decreases
- D. No association in first interval

**Answer < A: CRP increase disease/cancer risk**

**Explanation:**

Epidemiologic studies suggest that in patients with several types of solid cancers, elevated circulating levels of CRP are associated with poor prognosis, whereas in apparently healthy individuals from the general population, elevated levels of CRP are associated with increased future risk of cancer of any type, lung cancer, and possibly colorectal cancer, but not breast or prostate cancer. The robust association between circulating levels of CRP and cancer risk may be due to (1) causality: elevated CRP levels cause cancer, (2) reverse causality: occult cancer increases CRP levels, (3) or confounding: a third factor, e.g. inflammation, increases both CRP levels and the risk of cancer.

---

**76. A child known case of HIV. His CD count is 50. Which vaccine is avoided in him/her**

- A. MMR
- B. TT
- C. DPT
- D. BCG

**Answer < A: MMR**

**Explanation:**

Contraindications for MMR vaccination include history of a severe (anaphylactic) reaction to a previous dose or to any component of the vaccine (such as gelatin or neomycin), pregnancy and immunosuppression.

---

**77. For functioning of a health centre with reference to evaluation, which is the most important determinant for assessing clinical management.**

- A. Input
- B. Process
- C. Structure

D. Outcome

**Answer < D: Outcome**

**Explanation:**

The outcome of medical care, in terms of recovery, restoration of function and of survival, has been frequently used as an indicator of the quality of medical care.

---

78. A male presented with urethral discharge as shown in figure? What can be the cause?



- A. Gonorrhoea
- B. B. Hemophyli Ducreii
- C. Syphillis
- D. HIV

**Answer < A: Gonorrhoe**

**Explanation:**

Many men with gonorrhoea are asymptomatic. When present, signs and symptoms of urethral infection in men include dysuria or a white, yellow, or green urethral discharge that usually appears one to fourteen days after infection

---



**79. A group of people had pastries late at night followed by bouts of vomiting early in the morning. What could be the cause?**

- A. *S. aureus*
- B. *B cereus*
- C. *E. coli*
- D. *Lactobacillus*

**Answer < A: *S. aureus***

**Explanation:**

Staph food poisoning is characterized by a sudden start of nausea, vomiting, and stomach cramps. Most people also have diarrhea. Symptoms usually develop within 30 minutes to 8 hours after eating or drinking an item containing Staph toxin, and last no longer than 1 day. Severe illness is rare.

---

**80. A pregnant woman whose niece contracted varicella in same house was negative for serum antibodies of varicella. What would this mean?**

- A. She is susceptible to zoster
- B. She is susceptible to chicken pox
- C. She is immune to chicken pox
- D. She is immune to zoster

**Answer < A: She is susceptible to chicken pox**

**Explanation:**

A negative result indicates no detectable VZV antibody, but does not rule out acute infection. It should be noted that the test usually scores negative in infected patients during the incubation period and the early stages of infection.

---

**81. Child learning steps of hand hygiene**

- A. Cognitive
- B. Psychomotor
- C. Affective
- D. Affective & cognitive

**Answer < B: Psychomotor**

**Explanation:**

- Hand washing is one of the most important disease preventative skills you can teach your children. Teaching kids about hand washing is not just important to keep them healthier in childhood but all through life. Because of their age, children have less developed immune systems for fighting diseases and infections.
  - Hand hygiene is also a psychomotor skill critical for patient safety and needs to be taught correctly or students are being set up to fail.
- 

**82. What is the SI Unit of brightness/illuminance**

- A. Candella
- B. Luminance
- C. Lumen
- D. Lux

**Answer < D: Lux**

**Explanation:**

The SI unit for illuminance is **lux (lx)**. In the U.S. people sometimes use the non-SI term foot-candle when referencing illuminance. The term “foot-candle” means “the illuminance on a surface by a candela source one foot away”. One foot-candle is equivalent to one lumen per square foot which is approximately 10.764 lux.

---

**83. Receptor for absorption of glucose in intestine when person is given ORS is**

- A. SGLT-1
- B. SGLT-2
- C. GLP-1
- D. GLUT-1

**Answer < A: SGLT-1**

**Explanation:**

Sodium-glucose cotransporter (SGLT) activity mediates apical sodium and glucose transport across cell membranes. Cotransport is driven by active sodium extrusion by the basolateral sodium/potassium-ATPase, thus facilitating glucose uptake against an intracellular up-hill gradient.

---

**84. A 55 year old patient from chattisgarh presents with progressive muscle weakness, stiffness of both lower limbs & complete paralysis. Most important history asked**

- A. Dietary history
- B. Medical history
- C. Present illness
- D. socioeconomic

**Answer < A: Dietary history**

**Explanation:**

Neurolethyrism is the type associated with the consumption of legumes in the genus Lathyrus that contain the toxin ODAP. ODAP ingestion results in motorneuron death. The result is paralysis and muscle atrophy of the lower limbs.

---

**ENT**

**85. A women visited ENT opd with nasal obstruction. On examination greenish black crusts were present in the nasal cavity covering turbinate and septum. She also had merciful anosmia. What other sign will you find in this case on examination?**

- A. Polyp
- B. Hypertrophied inferior turbinate
- C. Roomy nasal cavity
- D. Foreign antibody

**Answer < A:** Roomy nasal cavity

**Explanation:**

- Chronic atrophic rhinitis, or simply atrophic rhinitis, is a chronic inflammation of the nose characterised by atrophy of nasal mucosa, including the glands, turbinate bones and the nerve elements supplying the nose. Chronic atrophic rhinitis may be primary and secondary. It is most commonly seen in females. It is reported among patients from lower socioeconomic groups.
- The nasal cavities become roomy and are filled with foul smelling crusts which are black or dark green and dry, making expiration painful and difficult.
- Microorganisms are known to multiply and produce a foul smell from the nose, though the patients may not be aware of this, because the nerve endings (responsible for the perception of smell) have become atrophied. This is called merciful anosmia.
- Patients usually complain of nasal obstruction despite the roomy nasal cavity, which can be caused either by the obstruction produced by the discharge in the nose, or as a result of sensory loss due to atrophy of nerves in the nose, so the patient is unaware of the air flow. In the case of the second cause, the sensation of obstruction is subjective.
- Bleeding from the nose, also called epistaxis, may occur when the dried discharge (crusts) are removed.
- Septal perforation and dermatitis of nasal vestibule can occur. The nose may show a saddle-nose deformity.

- Atrophic rhinitis is also associated with similar atrophic changes in the pharynx or larynx, producing symptoms pertaining to these structures. Hearing impairment can occur due to Eustachian tube blockage causing middle ear effusion.

**86. A 35 year old male presented with epistaxis . Conservative management was done to stop the bleeding which failed . What is the next step of management?**

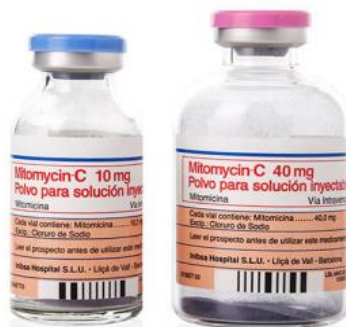- A. Endoscopic Sphenopalantine artery ligation
- B. ICA ligation
- C. ECA ligation
- D. Maxillary artery ligation

**Answer < A:** Endoscopic Sphenopalantine artery ligation

**Explanation:**

Endoscopic ligation of sphenopalatine artery is done in cases that do not respond to conservative management. In cases that do not respond to this, maxillary artery ligation, ECA ligation is done in that order.

**87. Which of the following is the topical use of the medicine shown in the image:**



- A. Subglottic stenosis
- B. Inlay type I myringoplasty
- C. Post-adenoidectomy to control bleeding
- D. Rhino cerebral mucormycosis

**Answer < A:** Subglottic stenosis

**Explanation:**

Mitomycin C is used to control or prevent stenosis. It is also used to treat pre existing stenosis. It is used in nasal surgeries like FESS, septoplasty, tracheal stenosis after tracheostomy, and laryngeal stenosis. Mitomycin C is also used to treat intubation granuloma.

---

**88. A post tonsillectomy child was lying in the ward. He started bleeding in the ward. Which of the following should be done**

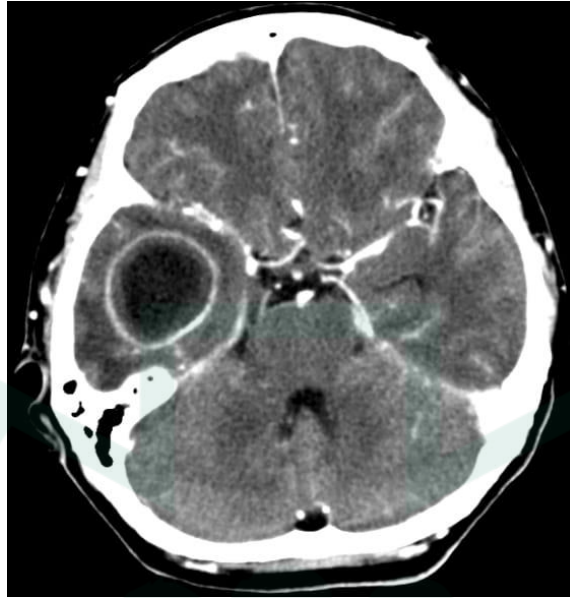
- A. Take to OT, remove the clot & re-ligation
- B. Take to OT & pressure packing
- C. Cautery
- D. Conservative management

**Answer < A:** Take to OT, remove the clot & re-ligation

**Explanation:**

This is a case of reactionary haemorrhage because the child is in the ward and the bleeding is occurring within 24hrs of surgery. Pressure packing and cautery are done for primary bleeding. In reactionary and secondary bleeding, re-ligation is the main modality of management.

89. Patient with a history of chronic middle ear infection now presents with neurological manifestations, headache and vomiting. CT Brain is shown. What is the probable diagnosis?



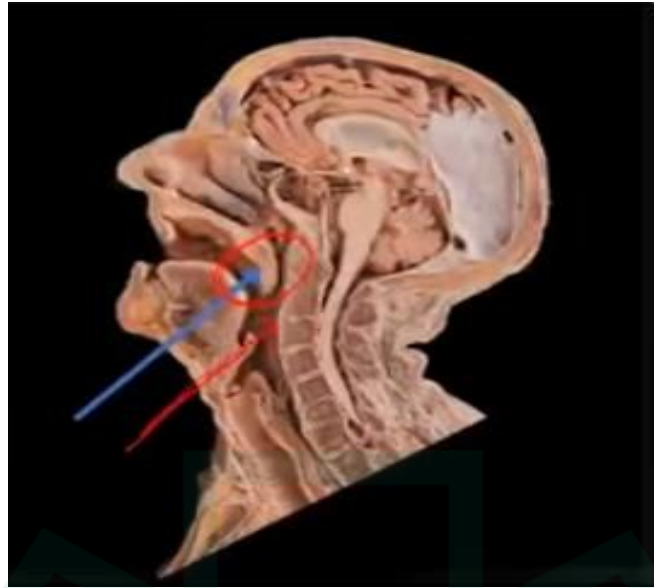
- A. Extradural Abscess
- B. Cerebral Abscess
- C. Temporal lobe Abscess
- D. Meningitis

**Answer < C:**Temporal Abscess

**Explanation:**

A ring like mass is noted on CT Brain, which is characteristic of temporal abscess. Most common cause of brain abscess is CSOM. The pathogen enters the ear and reaches the tegmen tympani resulting in temporal lobe abscess. It can also enter through the sinodural abscess resulting in posterior fossa abscess.

- 
90. A patient was admitted with skull base trauma. The doctor was testing the marked structure. Which of the following nerves was being tested:



- A. Vagus
- B. Facial nerve
- C. Glossopharyngeal nerve
- D. Trigeminal nerve

**Answer < C:** Glossopharyngeal Nerve

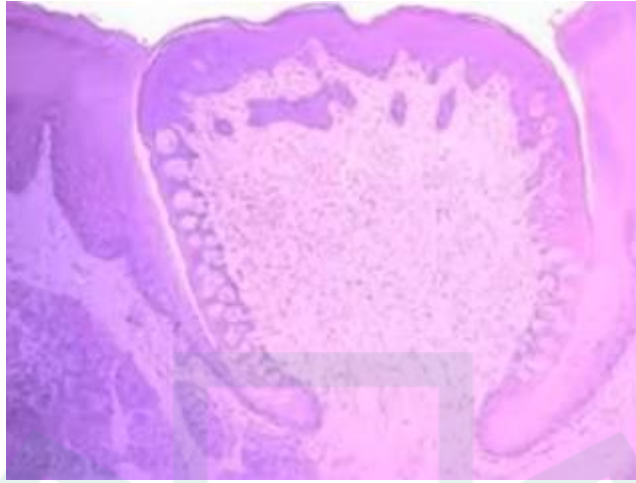
**Explanation:**

The structure being examined is glossopharyngeal nerve.

---



91. Identify the papillae of the tongue shown in the image below:



- A. Circumvallate
- B. Fungiform
- C. Filiform
- D. Foliate

**Answer < C:** Circumvallate

**Explanation:**

- The round shaped papilla shown in the image is circumvallate papilla.
- Fungiform papillae are mushroom shaped
- Filiform is cone shaped papilla
- Foliate is club shaped papilla

---

## Ophthalmology

92. A 33 year old female patient presented with inability to see the right side from both the eyes What is the most probable cause

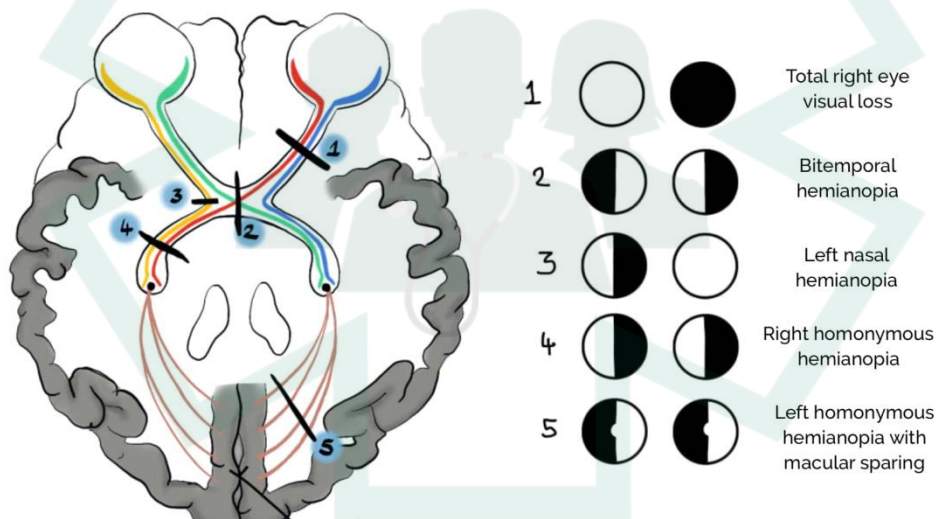
- A. Injury to Left Optic Tract
- B. Right occipital lobe lesion
- C. Optic chiasma lesion
- D. Right optic nerve lesion

**Answer < A:** Injury to Left Optic Tract

**Explanation:**

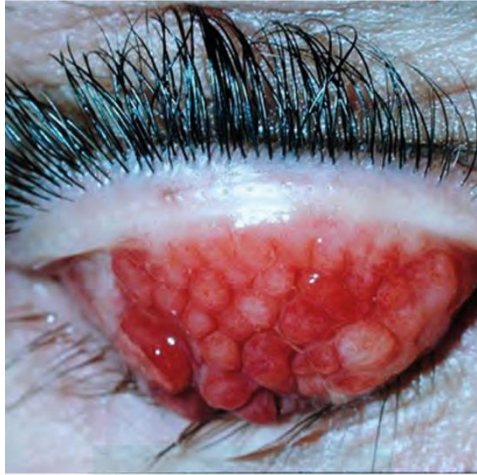Lesions of left optic tract result in Right homonymous Hemianopia..

**Various visual pathway defects include:**



**93. A patient with contact lens since 2 years presented with the below features.**

**What is the most probable cause.**



- A. Giant Papillary conjunctivitis
- B. Trachoma
- C. Vernal Keratoconjunctivitis
- D. OSSN

**Answer < A:** Giant papillary conjunctivitis

**Explanation:**

Giant papillary conjunctivitis is a syndrome that occurs in both hard and soft contact lens wearers and is characterized by increased mucus, itching, decreased lens tolerance, and giant papillae in the upper tarsal conjunctiva. It develops in as few as three weeks with soft lens wearers but also occurs after months or even years of successful wear. The histology is characterized by basophils, eosinophils, and mast cells in the epithelium, and these cells as well as increased numbers of lymphocytes, plasma cells, and polymorphonuclear leukocytes in the stroma. The syndrome may be immunologic in origin with deposits on the lenses as the antigen, and the syndrome may be a major cause of difficulty in wearing contact lenses once they have been successfully fit.

---

**94. A 15 year old girl patient does not want to use specs for myopic astigmatism. What is the best alternative for her?**

- A. ICL
- B. FEMTO Lasik

- C. LASIK
- D. Spherical Specs

**Answer < A:** ICL

**Explanation:**

the minimum age required to be eligible for LASIK surgery is 18 years.

Implantable Contact Lenses (ICL), the ICLs are micro-thin lenses placed inside the eye to correct short-sightedness (myopia), far-sightedness (hyperopia) and astigmatism. The procedure can be reversed and can be used to treat a high range of correction needs. For those with thin or abnormal corneas, Keratoconus and dry eye, this is an excellent alternative to laser eye surgery

---

**95. A boy working on a hammer & chisel had a Foreign body entering eye. Detrimental investigation for this boy is**

- A. X-ray
- B. B scan orbit
- C. CT Scan
- D. MRI

**Answer < D:** MRI

**Explanation:**

MRI is contraindicated in the presence of metallic foreign bodies/implants in the patient's body.

---

**96. A child presenting with whitish pupillary reflex was treated with enucleation. Histopathology of the specimen showed Flexner Wintersteiner rosettes. What is the diagnosis?**

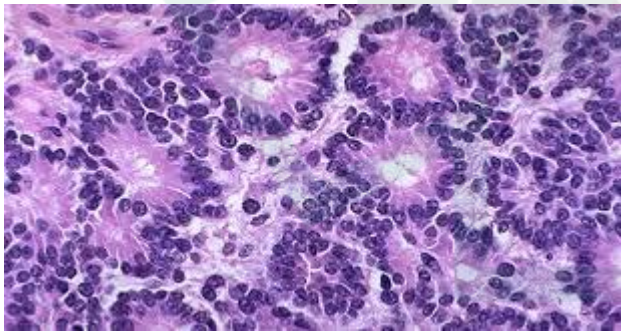
- A) Retinoblastoma

- B) Rhabdomyosarcoma
- C) Medulloblastoma
- D) Astrocytoma

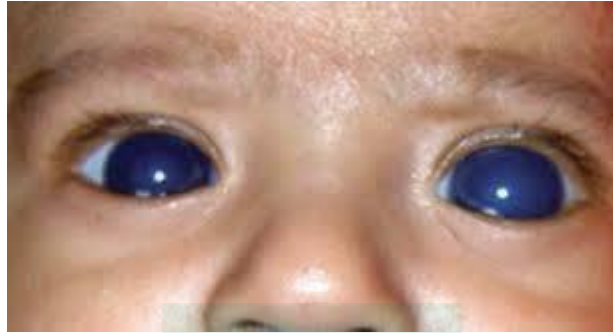**Answer < A:** Retinoblastoma

**Explanation:**

- Retinoblastoma is the most common intraocular malignancy of childhood and infancy accounting for 3% of all pediatric cancers. It is caused by inactivation of *RB1* genes commonly known as tumor suppressor gene. Incidence of retinoblastoma ranges approximately worldwide at one case per 15 000-20 000 live births, which corresponds to about 9000 new cases every year.. There is no racial or gender predisposition. The sign of retinoblastoma is a white pupil, called leukocoria, strabismus, painful blind eye and loss of vision.
- On microscopic examination, retinoblastoma reveals a tumor composed of small hyperchromatic cells with a high nuclear to cytoplasmic ratio with large areas of necrosis and multifocal area of calcifications. Tumour differentiation are categorized into well differentiated [ $>50\%$  known as Homer-Wright (HW) rosettes] or poorly differentiated [ $<50\%$  known as Flexner-Wintersteiner (FW) rosettes]



97. A one month baby presents with watering and increased corneal size. What is the diagnosis?



- A. Buphthalmos
- B. Hurlers Syndrome
- C. Galactosemia
- D. Cataract

**Answer < A:** Buphthalmos

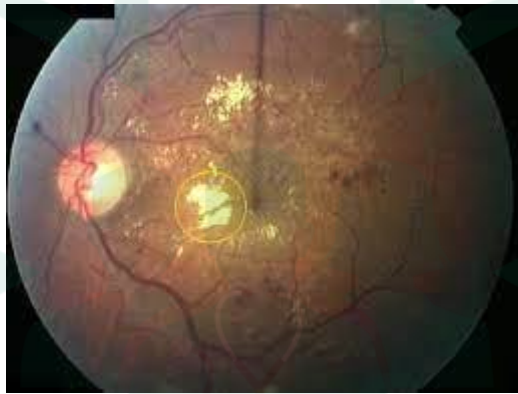
**Explanation:**

Primary congenital glaucoma (PCG) is a rare disease due to genetically-determined abnormalities in the trabecular meshwork and anterior chamber angle resulting in elevated intraocular pressure (IOP), without other ocular or systemic developmental anomalies. Other terms have been used previously to describe this entity, including trabeculodysgenesis, goniodysgenesis and primary infantile glaucoma, however the term PCG replaces these in the 2013 International Classification of Childhood Glaucoma. There are three variants based on the age of presentation as follows:

- newborn onset (0-1 month)
- infantile onset (>1-24 months)
- late onset or late-recognized (>24 months)
- spontaneously arrested cases (very rare, classic findings of eye stretching including Haab striae with normal IOP; must follow as glaucoma suspects nonetheless)

PCG commonly presents between the ages of 3-9 months, but the most severe form is the newborn onset. Elevated IOP is associated with the classic “triad” of symptoms (photophobia, epiphora and blepharospasm), which occurs due to rapid expansion of the child’s eye causing buphthalmos (Greek = “ox eye”), corneal enlargement, horizontal or oblique breaks in Descemet's membrane (Haab striae) and subsequent corneal edema and opacification.

**98. An elderly woman presented with gradual painless diminution of vision. The fundus picture is shown below. What is the diagnosis.**



- A. Hard Exudates in Diabetic Retinopathy
- B. Flame shaped haemorrhages in Hypertensive Retinopathy
- C. Soft Exudates in Hypertensive Retinopathy
- D. CRVO

**Answer < A:** Hard Exudates in Diabetic Retinopathy

**Explanation:**

The deposition of hard macular exudates is a sight threatening consequence of macular edema in patients with diabetes mellitus. Visual impairment has been correlated with the deposition of hard foveal exudates which are one of the most common and early clinical signs of diabetic retinopathy. Hard exudates are lipid and lipoprotein deposits and appear as white, yellowish or waxy lesions situated mainly in the outer plexiform layer of the retina. Large deposits of hard exudates increase

the risk of developing subretinal fibrosis, which is one of the most devastating sequelae of diabetic maculopathy.

---

**99. A patient complained of gradual diminution of vision. On examination the patient had dry eyes and a rough corneal surface. What could be the deficiency in the patient causing these manifestations.**

- A. Iron
- B. Protein
- C. Niacin
- D. Retinoic Acid

**Answer <D:** Retinoic Acid

**Explanation:**

An association between eye dryness and vitamin A deficiency is well known. Vitamin A is an important component for the visual pigments and the integrity of the ocular surface, and it is used in the treatment of peripheral vision loss, age-related macular degeneration, retinitis pigmentosa, and superior limbic keratoconjunctivitis. Dry eye disease can result from vitamin A deficiency, with mild deficiency resulting in conjunctival changes and severe deficiency resulting in xerophthalmia. Topical and oral preparations of retinoic acid are used to treat this condition.

---

**100. A young boy with thin built and long fingers presents with diminished vision. On examination subluxation of lens is observed and cystathione synthase deficiency was detected. Which aminoacid should the patient be supplied with?**

- A. Serine
- B. Tyrosine
- C. Methionine
- D. Cysteine



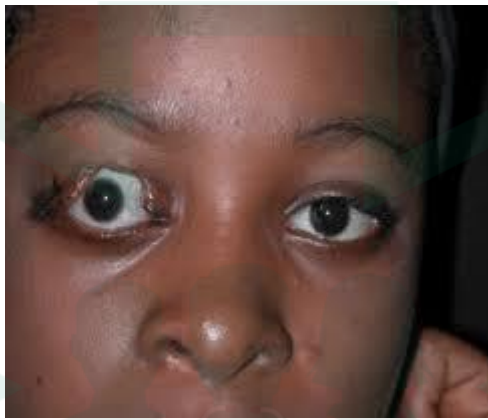**Answer <D:** Cysteine

**Explanation:**

This is a case of ectopia lentils due to homocysteinuria. It is managed with cysteine and vitamin B6 supplementation.

---

**101. What is the most likely complication of the condition shown in the image below?**



- A. Cataract
- B. Exposure Keratitis
- C. Difficulty in eye movement
- D. Glaucoma

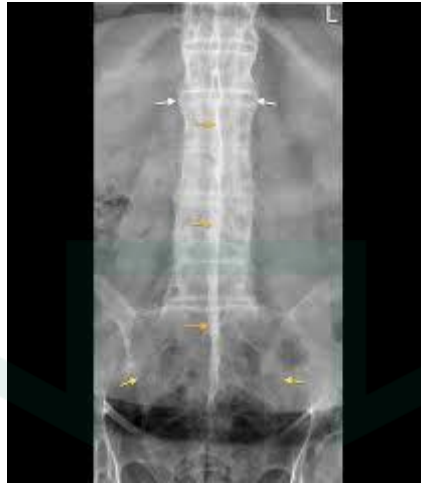**Answer <B:** Exposure Keratitis

**Explanation**

Due to a deficient eye lid, the cornea is always exposed to the external environment resulting in exposure keratitis and secondary bacterial infections.

---

102. Young male presents with acute redness of eye. His X-Ray spine is shown below. What is the condition?



- A. Ankylosing Spondylitis
- B. Psoriatic Arthritis
- C. Rheumatoid Arthritis
- D. Sjogren Syndrome

**Answer <A:** Ankylosing Spondylitis

**Explanation:**

Acute red eye in a young male with morning stiffness is characteristic of acute anterior uveitis along with ankylosing spondylitis. Other related conditions are psoriatic arthritis, reiter syndrome, juvenile rheumatoid arthritis.

---

103. A patient has been diagnosed with Primary Open Angle Glaucoma. On eliciting history, it was observed that the patient is a known case of bronchial asthma. What is the drug of choice for POAG in this patient?

- A. Latanoprost
- B. Gemeprost
- C. Carboprost

D. Alprostadil

**Answer: A - Latanoprost**

**Explanation:**

Beta blockers are contraindicated in cases of POAG along with a history of bronchial asthma as they result in further constriction of airways and precipitation of asthma. Resting and provoked airway function and asthma symptoms are unaffected by latanoprost treatment in patients with asthma with no previous exposure to corticosteroids. Latanoprost can be used in patients with glaucoma and concomitant bronchial asthma.

---

## Medicine

**104. Pt. has h/o vomiting & doctor gave antiemetic. Patient developed abnormal movements. What would be given**

- A. Methyl dopa
- B. Benzhexol
- C. Hyoscine
- D. Cyproheptadine

**Answer: B Benzhexol**

**Explanation:**

Trihexyphenidyl, aka also known as benzhexol, trihex, Artane, or even THP is an antiparkinsonian agent of the antimuscarinic class. It was approved by the FDA for the treatment of Parkinson's

ARTANE (trihexyphenidyl) is indicated as an adjunct in the treatment of all forms of parkinsonism (postencephalitic, arteriosclerotic, and idiopathic). It is often useful as adjuvant therapy when treating these forms of parkinsonism with levodopa.

---

**105. A 56 yr old pt. Has developed excruciating chest discomfort in past 72 hours relieved on GTN spray. TROP I is normal. ECG shows feature of LVH with T wave flattening. He is already on statins, aspirin & metoprolol 50mg. What is next best step?**

- A. LMWH
- B. Increase beta blocker dose
- C. IV NTG Drip
- D. Add tap clopidogrel

**Answer: A LMWH**

**Explanation:**

Given clinical scenario is pointing towards the diagnosis of unstable angina.

A number of LMWHs-dalteparin, enoxaparin and nadroparin-have been evaluated in unstable angina. In a small open trial, nadroparin reduced the risk of ischaemic outcomes compared with aspirin alone or a combination of aspirin and standard heparin.

Low-molecular-weight heparin (LMWH) is a class of anticoagulant medications. They are used in the prevention of blood clots and treatment of venous thromboembolism (deep vein thrombosis and pulmonary embolism) and in the treatment of myocardial infarction.

---

**106. Known case of HIV with cough of sputum production & fever with examination finding of consolidation in right infrascapular area with x-ray showing right lower consolidation with CD4 of 55. What is the most common cause of this in these?**

- a. Staph aureus
- b. Strep pneumonia
- c. Mycoplasma
- d. P. jiroveci

**Answer: B. Strep pneumonia**

**Explanation:**

HIV-1 seropositive individuals are particularly susceptible to infections with encapsulated bacteria, such as *Streptococcus pneumoniae*. In fact, pneumococcus is one of the most common bacterial pathogens affecting both HIV-1 infected children and adults.

Bacterial pneumonia can occur at any stage of HIV disease and at any CD4 cell count. However, as the CD4 cell count declines, the incidence of bacterial pneumonia increases as does the incidence of accompanying bacteremia and septicemia. The latter is especially the case with *S. pneumoniae*.

---

**107. A patient with mediastinal mass was diagnosed with red cell aplasia. What is the probable cause?**

- A. Bronchogenic carcinoma
- B. NHL
- C. Thymic neoplasia
- D. T cell ALL

**Answer: C. Thymic Neoplasia**

**Explanation**

Acquired Pure Red Cell Aplasia is thought to be an autoimmune disorder possibly caused either by a tumor of the thymus gland, certain drugs or a viral infection. It is one of a group of bone marrow failure syndromes.

---

**108. A software engineer presented to OPD with complaints of easy fatiguability, He gives a history of sitting in front of the computer for 12-14 hrs a day and consuming junk food and less fruits and vegetables. CBC picture showed Hb concentration as 7gm%, MCV-120. What is the most likely cause of anemia?**

- A. Folate deficiency

- B. Sideroblastic anemia
- C. Cyanocobalamin deficiency
- D. Acute blood loss

**Answer: A Folate deficiency**

**Explanation**

Folate, or folic acid, is a type of B vitamin. It helps to:

- make DNA
- repair DNA
- produce red blood cells (RBCs)

If you don't have enough folate in your diet, you may end up with a folate deficiency. Certain drinks and foods, such as citrus juices and dark green vegetables, are particularly good sources of folate. Not eating enough folate can lead to a deficiency in just a few weeks. Deficiency may also occur if you have a disease or genetic mutation that prevents your body from absorbing or converting folate to its usable form. Folate deficiency can cause anemia.

---

**109. False about pheochromocytoma**

- A. Propranolol is preferred drug for hypertension control
- B. Surgery is t/t of choice
- C. VMA are diagnostic test
- D. catecholamines are diagnostic test

**Answer: A Propranolol is preferred drug for hypertension control**

**Explanation**

Phenoxybenzamine, a non-selective alpha blocker, is the most common medication used to alpha block patients prior to pheochromocytoma resection.

**110. A 50 yr old pt. With renal insufficiency was recently operated for pyelolithotomy, which drug you will give for post op analgesia.**

- A. Diclofenac sodium
- B. Naproxen
- C. Indomethacin
- D. Acetaminophen

**Answer: D Acetaminophen**

**Explanation**

Acetaminophen is the drug often recommended for occasional use in patients with kidney disease. Various studies have been conducted & it was found that The combination of intravenous paracetamol 1 gr and ketamine 0.5 mg/kg resulted in an overall reduction in pain scores, decreased postoperative analgesic requirements, and lower agitation score compared with intravenous paracetamol 1 gr and tramadol 0.7 mg/kg for patients undergoing renal surgery.

---

**111. 68/m cough with sputum, bronchial sounds. RR-20/min, urea-44mg/dl, BP-110/70mmhg. Next step?**

- A. Home Rx
- B. Admit in ICU without MV
- C. Admit in ICU with MV
- D. Room admission

**Answer: D Room admission**

**Explanation**

**Table 1. CURB-65 Scoring<sup>46</sup>**

Symptom	Points
Confusion	1
Urea: BUN >19 mg/dL (>7 mmol/L)	1
Respiratory rate ≥30 breaths/min	1
Systolic BP <90 mm Hg or diastolic BP ≤60 mm Hg	1
Age ≥65 years	1
Total	_____

Score	Risk	Disposition
0 or 1	1.5% mortality	Outpatient care
2	9.2% mortality	Inpatient versus observation admission
≥3	22% mortality	Inpatient admission; consider ICU admission with score of 4 or 5

Abbreviations: BP, blood pressure; BUN, blood urea nitrogen; ICU, intensive care unit.

**112. 3 patients feel numb finger tips. Facial skin is tightened. ANA +ve. IF nucleolar pattern**

- A. Systemic sclerosis
- B. Sjogren's syndrome
- C. SLE
- D. RA

**Answer: A Systemic sclerosis**

**Explanation**

Systemic sclerosis (SS) is **an autoimmune disorder**. This means it's a condition in which the immune system attacks the body. Healthy tissue is destroyed because the immune system mistakenly thinks it's a foreign substance or infection. There are many kinds of autoimmune disorders that can affect different body systems.

Nucleolar pattern, is common in people with scleroderma.

**113. A hyperventilating patient has ABG value of pH=7.53, pCO2= 20mmHg, HCO3=26meq**

- A. Respiratory acidosis
- B. Respiratory alkalosis



- C. Metabolic acidosis
- D. Metabolic alkalosis

**Answer: B Respiratory alkalosis**

### Explanation

Respiratory alkalosis is a primary decrease in carbon dioxide partial pressure ( $P_{CO_2}$ ) with or without compensatory decrease in bicarbonate ( $HCO_3^-$ ); pH may be high or near normal. Cause is an increase in respiratory rate or volume (hyperventilation) or both. Respiratory alkalosis can be acute or chronic.

---

**114. Patient presents with breathlessness & wheezing. Absolute Eosinophil count is 500. Miliary pattern on CXR. Diagnosis**

- A. Miliary TB
- B. Tropical pulmonary eosinophilia
- C. Bronchial asthma
- D. Hypersensitivity pneumonitis

**Answer: B Tropical pulmonary eosinophilia**

### Explanation

- Tropical (pulmonary) eosinophilia, or TPE, is characterized by coughing, asthmatic attacks, and an enlarged spleen, and is caused by *Wuchereria bancrofti*, a filarial infection. It occurs most frequently in India and Southeast Asia. Tropical eosinophilia is considered a manifestation of a species of microfilaria.
  - Absolute eosinophilia counts are usually more than 3, cells 000 /mm<sup>3</sup> and may range from 5,000 to 80,000. Erythrocyte sedimentation rate is elevated in 90% of cases and returns to normal following specific treatment. Microfilariae are rarely seen in the peripheral blood.
- 

**115. Breathing difficulty with generalized weakness. On auscultation a mid diastolic murmur with prominent wave is seen in**

- A. TS
- B. MS
- C. MR
- D. TR

**Answer: ATS**

**Explanation**

- Tricuspid stenosis (TS) is narrowing of the tricuspid orifice that obstructs blood flow from the right atrium to the right ventricle. Almost all cases result from rheumatic fever. Symptoms include a fluttering discomfort in the neck, fatigue, cold skin, and right upper quadrant abdominal discomfort.
- It has strong or forceful right atrial contraction

---

**116. Patient behaving strangely, & CNS features were described. Urine osm=1000 & plasma osmolality= 250**

- A. Hyponatremia
- B. Hypernatremia
- C. Hypokalemia
- D. Hyperkalemia

**Answer: A Hyponatremia**

**Explanation**

- A condition that occurs when the level of sodium in the blood is too low.
- With this condition, the body holds onto too much water. This dilutes the amount of sodium in the blood and causes levels to be low.
- Symptoms include nausea, headache, confusion and fatigue.
- Limited fluid intake, medication and hospitalisation may be required.

117. 30 y/F, 70 kg man with serum sodium=120. Calculate total sodium deficit

- A. 420
- B. 840
- C. 1400
- D. 280

**Answer: B840**

**Explanation**

Formula for sodium deficit= TB water% X wt.(Kgs) X (Desired Na<sup>+</sup> - Actual Sodium)

- =0.6 x 70 x (140-120)
- =840meq

---

118. Hypertension with peripheral edema & CKD

- A. Aliskiren
- B. Chlorthalidone
- C. Prazosin
- D. Beta blocker

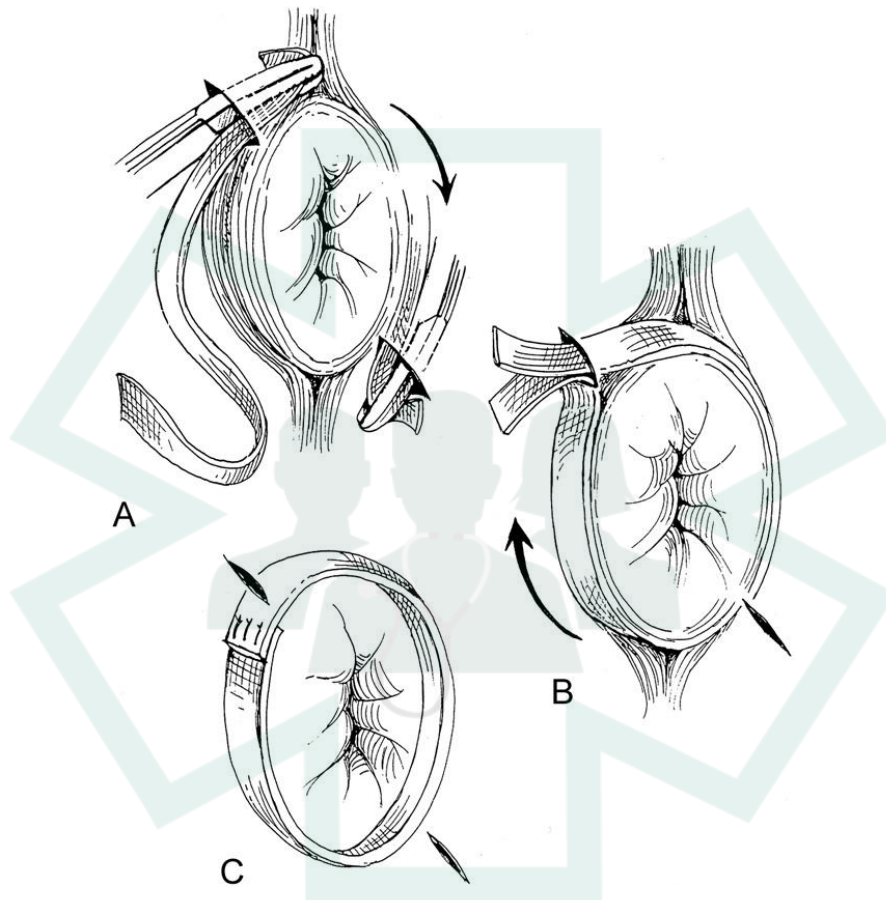
**Answer: B Chlorthalidone**

**Explanation**

Chlorthalidone is a prescription drug used to treat high blood pressure (hypertension). Lowering high blood pressure helps prevent strokes, heart attacks, and kidney problems. It is also used to reduce extra salt and water in the body caused by conditions such as heart failure, liver disease, and kidney disease.

## Surgery

119. What surgery is shown here in the image



- A. Thiersch wiring
- B. Wells procedure
- C. Aktemeier operation
- D. Hemorrhoidectomy

**Answer: A Thiersch wiring**

**Explanation**

Thiersch procedure (anal encirclement) is performed frequently in patients with old age or high risks with rectal prolapse. It is a simple procedure **using a suture or prosthesis that narrows the anus.**

---

**120. Post MRM patient presented with upper limb swelling . What is the most probable cause**

- A. Upper limb Lymphedema
- B. Angiosarcoma
- C. Recurrence
- D. Metastasis

**Answer: A** Upper limb Lymphedema

**Explanation**

Post mastectomy lymphoedema is MC upper limb lymphoedema. (Ranges from 2- 10%)  
Factors increasing risk of lymphoedema.

- i) Lymph node removal
- ii) Radiation to axilla
- iii) Infection in the upper limb.

---

**121. Repair done for direct inguinal hernia**

- A. Lichtenstein repair
- B. Bassini's repair
- C. Herniotomy
- D. All

**Answer: A** Lichtenstein repair

**Explanation**

Surgery of Choice Lichtenstein tension free mesh hernioplasty.  
It has least recurrence rate

---

**122. A patient presented with RTA leading to breathlessness and decreased air entry into right lung and patient is hypotensive. What is the next step?**

- A. Needle inserted at 2nd ICS in MCL
- B. Needle inserted at 5th ICS in mid axillary
- C. Fluid resuscitation using wide bore cannula
- D. Wide bore needle decompression

**Answer: B**

**Explanation**

The patient has developed tension pneumothorax where on diagnosis by FAST we get Seashore sign or Stratosphere sign in M mode.

**And managed by-**

- In adults - wide bore needle now inserted in Mid axillary line at 5th ICS
  - In children- same 2nd ICS at MCL is allowed
- 

**123. After total thyroidectomy, the surgeon is unable to extubate and the patient shows cyanosis and respiratory distress. Cause of unable to extubate this-**

- A. Bilateral recurrent laryngeal nerve palsy
- B. UL recurrent laryngeal nerve palsy
- C. Hemorrhage
- D. Supra laryngeal nerve palsy

**Answer: A**

**Explanation**

- Postoperative respiratory distress
- Laryngeal edema (MC)
- Bilateral RLN injury
- Laryngomalacia
- Tension hematoma

**124. Asymptomatic Varicose veins under CEAP scoring will be**

- A. C2a
- B. C2b
- C. C3a
- D. C3b

**Answer: A C2a**

**Explanation**

**Table 1: CEAP Grading System**

C <sub>0</sub>	No visible or palpable signs of venous disease
C <sub>1</sub>	Telangiectasia or reticular veins (thread veins)
C <sub>2</sub>	Varicose veins (diameter >3mm)
C <sub>3</sub>	Oedema
C <sub>4</sub>	Changes in the skin and subcutaneous tissue: pigmentation, eczema, lipodermatosclerosis or atrophic blanche
C <sub>5</sub>	Healed venous ulcer
C <sub>6</sub>	Active venous ulcer

**125. 60 years old male patient has antral carcinoma which is spreading to the head of the pancreas and multiple small metastasis to the right lobe of liver. What will be the best treatment?**

- A. Whipple's surgery
- B. Gastrectomy + Right lobectomy
- C. Gastrojejunostomy
- D. Palliative care

**Answer: C Gastrojejunostomy**

**Explanation**

Obstruction of the duodenum occurs in 15% cases approx. If this occurs early in the course of disease, surgical bypass by gastrojejunostomy is done.

---

**126. MC nerve injured during Submandibular gland surgery?**

- A. Lingual nerve
- B. Inferior alveolar nerve
- C. Hypoglossal nerve
- D. Nerve to mylohyoid

**Answer: A Lingual nerve**

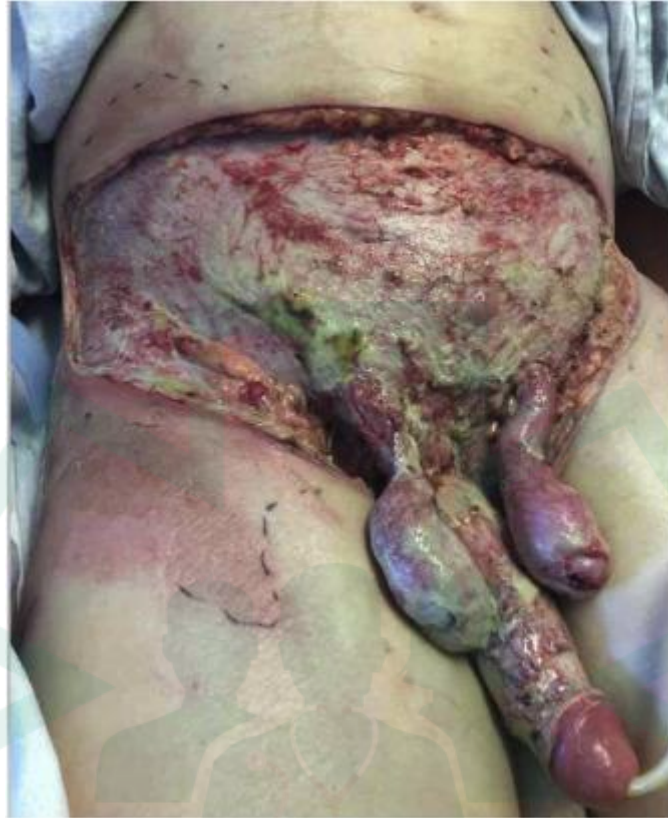**Explanation**

Submandibular glands are paired below the mandible on either side.  
MC nerve injured Lingual nerve > Hypoglossal nerve

---



127. Which statement is true among all?



- A. Associated with mixed aerobic and anaerobic infection
- B. Orchidectomy should be done
- C. Anti- gas gangrene serum should always be used
- D. Urinary diversion done

**Answer: A** Associated with mixed aerobic and anaerobic infection

**Explanation**

Necrotizing fasciitis which involves perineal region.

Synergistic gangrene (aerobic + anaerobic)

Testis is not involved in this condition due to the presence of dual blood supply.

**128. 85 year with Ca prostate with Gleason 6 and PSA <8 ng/ml. Best management?**

- A. TURP
- B. Radiation
- C. Radical prostatectomy
- D. Keep on active surveillance

**Answer: D Keep on active surveillance**

**Explanation**

Well-differentiated tumors have a Gleason sum of 2–4, moderately differentiated tumors have a Gleason sum of 5–6, and poorly differentiated tumors have a Gleason sum of 8–10.

To better assess risk and guide treatment selection, a combination of the initial T stage, Gleason score, and baseline PSA are used.

But here in the question as the age of patient is 85 years so the patient will have comorbidities. Therefore we will keep the patient on active surveillance.

---

**129. Post cholecystectomy, CBD stone detected after 2 years What type of stone is it?**

- A. Primary
- B. Secondary
- C. Tertiary
- D. Retained stone

**Answer: A Primary**

**Explanation**

Choledocholithiasis can be primary from stones originally formed in the choledocho or secondary from stones that have migrated from the gallbladder to the choledocho.

Residual or secondary choledocholithiasis was defined as those which appear in the first two years after cholecystectomy and primary choledocholithiasis was defined as those which appear two years after cholecystectomy.

---

**130. Gas under diaphragm is seen in-**

- A. Viscus perforation
- B. Liver abscess
- C. Spontaneous rupture of oesophagus
- D. Empyema Thorax

**Answer: A Viscus perforation**

**Explanation**

The most common cause of gas under diaphragm is hollow viscous perforation. In 10% of cases it can be due to rare causes, both abdominal and extra-abdominal, one of them being intra abdominal infection by gas forming organisms.

---

**131. Left hypochondrium contusion SBP- 70 mm Hg PR 110. So what needs to be done next?**

- A. FAST
- B. CECT
- C. DPL
- D. Abdomen X-ray

**Answer: A**

**Explanation**

The Focused Assessment with Sonography in Trauma (FAST) is an ultrasound protocol developed to assess for hemoperitoneum and hemopericardium. As FAST exam in less than 5 minutes, and its use decreases time to surgical intervention, patient length of stay, and rates of CT and DPL.

---

**132. Mr Ramu faced an accident and had straddle injury and presents with blood at urethral meatus. What will be the next step?**

- A. Foleys catheter insertion
- B. SPC and drain the urine
- C. Do retrograde urethrogram
- D. CECT pelvis is taken

**Answer: B**

**Explanation**

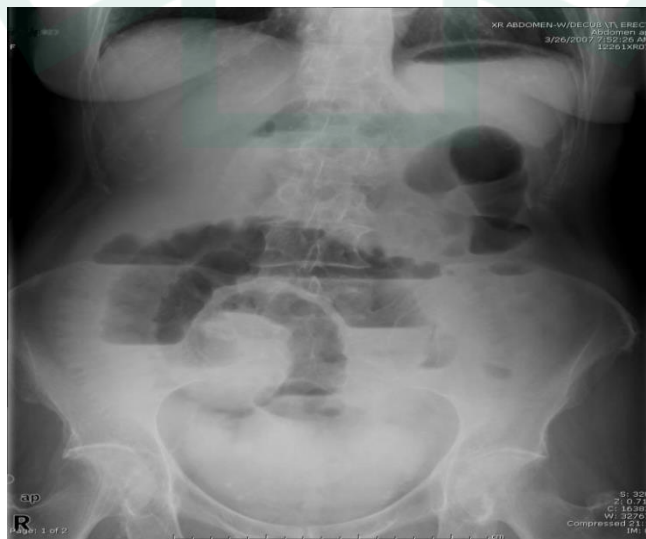Suspected urethral injury after blunt perineal trauma when man cannot void, when there is perineal bruising and when there is blood at the urethral meatus.

Diagnosis is made by urethrography using water soluble contrast

The safest initial management is to insert a suprapubic catheter (SPC)

---

**133. Identify the condition?**



- A. Intestinal obstruction
- B. Valvulae conniventes

- C. Haustrations
- D. None

**Answer: A**

**Explanation**

Stepladder sign represents the **appearance of distended small bowel loops with gas-fluid levels that appear to be stacked on top of each other**, typically observed on erect abdominal radiographs in the setting of small bowel obstruction.

---

**134. What is the metabolic finding seen in a baby with CHPS?**

- A. Hyperchloremic hypernatremic metabolic alkalosis
- B. Hypochloremic hypernatremic metabolic acidosis
- C. Hypochloremic hyponatremic metabolic alkalosis
- D. Hyperchloremic hyponatremic metabolic alkalosis

**Answer: C**

**Explanation**

- CHPS
  - MC surgical cause of vomiting in infants
  - MC age of presentation- 4 weeks
  - Palpation of a olive like structure in right upper quadrant is pathognomonic
  - Hypochloremia, hypokalemia and metabolic alkalosis happens during severe vomiting
- 

## Obs/Gyne

**135. A Pregnant woman came for a routine antenatal checkup . She had a history of twin pregnancy 1 year ago. What will be gravida and para**

- A. G2P2
- B. G2P3

- C. G2P1
- D. G2P0

**Answer: C G2P1**

**Explanation**

1. Gravidity is defined as the number of times that a woman has been pregnant. Parity is defined as the number of times that she has given birth to a fetus with a gestational age of 24 weeks or more, regardless of whether the child was born alive or was stillborn.
2. For example, a woman who is described as 'gravida 2, para 2 (sometimes abbreviated to G2 P2) has had two pregnancies and two deliveries after 24 weeks, and a woman who is described as 'gravida 2, para 0' (G2 P0) has had two pregnancies, neither of which survived to a gestational age of 24 weeks.
3. If they are both currently pregnant again, these women would have the obstetric history of G3 P2 and G3 P0 respectively. Sometimes a suffix is added to indicate the number of miscarriages or terminations a woman has had. So if the second woman had had two miscarriages, it could be annotated G3 P0+2.
  - A nulliparous woman (nullip) has not given birth previously (regardless of outcome).
  - A primagravida is in her first pregnancy.
  - A primiparous woman has given birth once. The term 'primip' is often used interchangeably with primagravida, although technically incorrect, as a woman does not become primiparous until she has delivered her baby.
  - A multigravida has been pregnant more than once.
  - A multiparous woman (multip) has given birth more than once.
  - A grand multipara is a woman who has already delivered five or more infants who have achieved a gestational age of 24 weeks or more, and such women are traditionally considered to be at higher risk than the average in subsequent pregnancies.
  - A grand multigravida has been pregnant five times or more.
  - A great grand multipara has delivered seven or more infants beyond 24 weeks of gestation.

Multiple pregnancies present a problem: a multiple gestation counts as a single event and a multiple birth should be interpreted as a single parous event, although this remains contentious. In a survey, only 20% of British midwives and obstetricians recognised a twin delivery as a single parous event - G1 P1 rather than G1 P2, revealing the potential lack of standardisation in our documentation.

**136. A Hypertensive patient wants to conceive . Which of the following medicines needs to be Stopped**

- A. Calcium Channel Blockers
- B. ACE inhibitors
- C. Alpha Methyl dopa
- D. Labetolol

**Answer: B ACE inhibitors**

**Explanation**

Both labetalol and methyldopa are considered safe for use in pregnant women, while angiotensin-converting enzyme (ACE) inhibitors and angiotensin II receptor blockers (ARB) are contraindicated during all trimesters of pregnancy based on their potential teratogenic and fetotoxic effects.

---

**137. A 27 year old woman who had delivered a female child 9 months back, came to the gynaecologist with complaints of absent periods since child birth. She has been using contraceptive methods as a family control measure. She was advised to get her serum beta hCG levels tested, which came out as 4.9 mIU/ml. Her prolactin level was 88ng/ml, and TSH was 3.8. What could be the reason for amenorrhea in this case?**

- A. Normal pregnancy
- B. Lactational amenorrhea
- C. Hypothyroidism
- D. Prolactinoma

**Answer: Option b) lactational amenorrhoea**

**Explanation**

Lactational amenorrhea is also called post partum infertility. It usually lasts up to 6 months postpartum, but may extend beyond this period in some cases. The suckling of the mother's nipple by the baby leads to increased production of prolactin by the pituitary. This inhibits the secretion of GnRH by the hypothalamus. Decreased GnRH in turn leads to decreased FSH and LH levels, which are responsible for ovulation. Hence, ovulation does not occur due to this decrease in LH and FSH levels.

---

**138. Uterine didelphys will cause all of the following symptoms except?**

- A. Transverse lie
- B. Endometriosis
- C. Repeated abortion
- D. Premature labor

**Answer: B Endometriosis**

**Explanation**

Many women with a double uterus have normal sex lives, pregnancies and deliveries.

But sometimes a double uterus and other abnormalities of uterine development are associated with:

- Infertility
- Miscarriage
- Premature birth
- Kidney problems
- Transverse lie

---

**139. Management of uterine septum?**

- A. Laparoscopic resection of septum
- B. Hysteroscopic resection of septum
- C. Uterine metroplasty
- D. Laparotomy and resection

**Answer: B Hysteroscopic resection of septum**

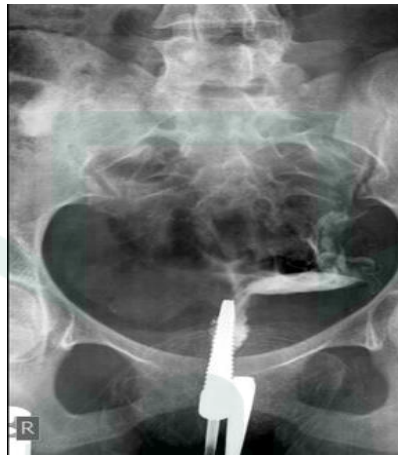
**Explanation**



Hysteroscopic treatment of uterine septa is a safe, simple, and effective procedure. It can be used for all types of uterine septa, it attains optimal obstetric outcomes, and it should be undertaken whenever a uterine septum is diagnosed.

---

**140. What is the modality of this test?**



- A. Hysterosalpingography
- B. Laparoscopy
- C. Hysteroscopy
- D. Saline infusion sonography

**Answer: A Hysterosalpingography**

**Explanation**

Hysterosalpingography, also known as uterosalpingography, is a radiologic procedure to investigate the shape of the uterine cavity and the shape and patency of the fallopian tubes. This means it is a special x-ray using dye to look at the womb and Fallopian tubes.

---

**141. A 24 year old female pt. With weeks of amenorrhea, left adnexal mass on USG, B-hcg 2500, no fetal heart rate. What's the management?**

- A. Expectant management
- B. Salpingectomy

- C. Single dose methotrexate
- D. Milking of tube

**Answer: C Single dose methotrexate**

**Explanation**

Methotrexate (MTX), a folic acid antagonist, inhibits DNA synthesis in actively dividing cells, including trophoblasts. Administered to properly selected patients, it has a success rate of up to 94%. The success in ectopic pregnancy depends mainly on  $\beta$ -hCG concentration.

**The criteria for MTX treatment of ectopic pregnancy are as follows:**

- Hemodynamic stability.
- Ability and willingness of the patient to comply with post-treatment monitoring.
- Pretreatment serum  $\beta$ -hCG concentration less than 5000 IU/L.
- Absence of ultrasound evidence of fetal cardiac activity.

---

**142. H/o primary infertility, 2 fibroids in the cornua, & both sides tubal blockage, ovulation of women & semen analysis is normal. Treatment ?**

- A. ART
- B. Lap Myomectomy
- C. Hysterectomy
- D. Uterine artery embolization

**Answer: B Lap Myomectomy**

**Explanation**

Laparoscopic Myomectomy, also called Robotic Myomectomy is a surgical procedure of removing fibroids through small abdominal incisions. Laparoscopic Myomectomy is suggested and advised for those who experience problems due to fibroids.

---

**143. Lady using OCP since 5 month. Amenorrhea since last 6 weeks. Which is best to calculate gestational age in this case?**

- A. 280 days from LMP
- B. 256 days from LMP
- C. CRL by USG
- D. Abdominal girth

**Answer: C CRL by USG**

**Explanation**

CRL is measured as the largest dimension of embryo, excluding the yolk sac and extremities. It is used as a primary measure of gestational age between 6-13 weeks. After 13 weeks, head circumference, biparietal diameter, and femur length measurements become more useful measurements for assessing fetal growth.

**144. Order of ligation of devascularization in PPH**

- A. Uterine artery, pudendal artery, vaginal artery
- B. Uterine artery, internal iliac, obturator artery
- C. Uterine artery, ovarian artery, internal iliac artery
- D. Uterine artery, ovarian artery, vaginal artery

**Answer: C Uterine artery, ovarian artery, internal iliac artery**

**Explanation**

Bilateral ligation of the uterine vessels (O'Leary stitch) is the preferred approach for controlling PPH from laceration of the uterine artery or branches of the utero-ovarian artery. If this does not control bleeding, the vessels of the utero-ovarian arcade are similarly ligated.

Hypogastric (internal iliac) artery ligation was pioneered by Howard Kelly for the treatment of intraoperative bleeding from cervical cancer prior to its application in postpartum hemorrhage (PPH).

**145. Patient with post molar evacuation, now has lesion in lungs cannon ball appearance .  
Which is the best management?**

- A. Hysterectomy
- B. Emaco regimen
- C. Inj. methotrexate
- D. Multiple dose of Inj. methotrexate

**Answer: B Emaco regimen**

**Explanation**

**Treatment protocol for high risk cases:**

EMACO Regimen

**Day 1**

- Actinomycin D 0.5 mg i.v. bolus
- Etoposide 100 mg/m<sup>2</sup> iv. in 500 ml normal saline over 30 min
- Methotrexate 100 mg/m<sup>2</sup> i.v. push slowly
- Methotrexate 200 mg/m<sup>2</sup> i.v. in 500 ml 5% dextrose over 12 hr

**Day 2**

- Actinomycin D 0.5 mg i.v. bolus
- Etoposide 100 mg/m<sup>2</sup> i.v. in 500 ml N saline over 30 min
- Folinic acid 15 mg i.m. 12-hourly × 4 doses starting 30 hr after commencing Methotrexate

**Day 8**

- Vincristine 1 mg/m<sup>2</sup> i.v. bolus (max. 2mg)
- Cyclophosphamide 600 mg/m<sup>2</sup> i.v. in 500 ml N saline over 30 min.

---

**146. Pregnant female with herpetic lesions in the vulva. Management is?**

- A. Acyclovir & elective Cs

- B. Induction of labor
- C. Acyclovir & allow spontaneous progression of labor
- D. Wait & watch

**Answer: A Acyclovir & elective Cs**

**Explanation**

- Genital herpes simplex virus (HSV) infection during pregnancy poses a risk to the developing fetus and newborn.
- Cesarean delivery is indicated in women with active genital lesions or prodromal symptoms, such as vulvar pain or burning at delivery, because these symptoms may indicate viral shedding. Although in the setting of recurrent active maternal disease the incidence of neonatal disease is low, cesarean birth is recommended because of the potentially serious nature of the disease.

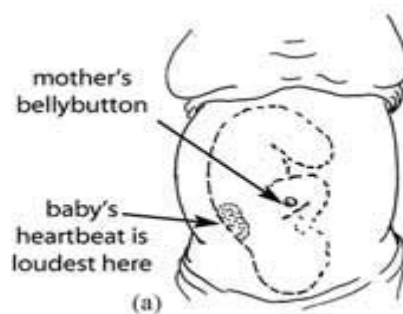---

**147. Patient with infraumbilical flattening & fetal heart rate heard laterally, what is the presentation?**

- A. Occipitoposterior
- B. Knee
- C. Brow
- D. Right dorsoanterior

**Answer: A Occipitoposterior**

**Explanation**



**148. Husband asks for paternal testing of his twins. One twin is found to be his son & other is not. Diagnosis?**

- A. Superfecundation
- B. Superfoetation
- C. Posthumous child
- D. None of the above

**Answer: A Superfecundation**

**Explanation**

Superfecundation is the fertilization of two or more ova from the same cycle by sperm from separate acts of sexual intercourse, which can lead to twin babies from two separate biological fathers. The term superfecundation is derived from fecund, meaning the ability to produce offspring.

---

**149. Teenage patient with transverse vaginal septum with dysmenorrhea & chronic pelvic pain. Diagnosis?**

- A. Endometriosis
- B. Tubovarian abscess
- C. Dermoid cyst
- D. Theca lutein cyst

**Answer: A Endometriosis**

**Explanation**

Secondary dysmenorrhea typically appears 12 months post menarche and is associated with progressively worsening pain, chronic pelvic pain (CPP), midcycle or acyclic pain, and irregular or heavy menstrual bleeding . Common etiologies include: endometriosis, adenomyosis and obstructive anomalies.

---

**150. 28 years old married female anxious about conception. C/o profuse vaginal discharge. No h/o itching. 12 days since LMP**

- A. Candida
- B. Trichomonas
- C. Bacterial vaginosis
- D. Physiological

**Answer: D Physiological**

**Explanation**

Normal physiological vaginal discharge is a white or clear, non-offensive discharge that changes with the menstrual cycle. It is thick and sticky for most of the cycle but becomes clearer, wetter, and stretchy for a short period around the time of ovulation.

---

**151. H/o recurrent abortions at 8,11& 22 weeks. Cardiac activity is normal in all the three. H/o of preeclampsia in last pregnancy. What is the most probable cause**

- A. Syphilis
- B. APLA
- C. TORCH
- D. GDM

**Answer: A Syphilis**

**Explanation**

- Syphilis may seriously complicate pregnancy and result in miscarriage, stillbirth, nonimmune hydrops, intrauterine growth restriction and perinatal death, and serious sequelae in surviving infected children.
  - Kassowitz Law:-As the no. of Pregnancy loss ↑ the period at which pregnancy ends also ↑.
  - Infections never leads to RPL Except Syphilis ( Perform VDRL Test).
  - TORCH Test have no role in RPL.
-

**152. Female missed OCP on 4 different days in 1st 2 weeks of menstrual cycle. What will you advise?**

- A. Continue taking pill
- B. Take all 4 pills at once & continue taking pills
- C. Adopt another method of contraception
- D. Continue current pack, consider additional contraceptive method for remaining days

**Answer: D Continue current pack, consider additional contraceptive method for remaining days**

**Explanation**

If two or more consecutive hormonal pills have been missed: ( $\geq 48$  hours since a pill should have been taken)

- Take the most recent missed pill as soon as possible (any other missed pills should be discarded).
- Continue taking the remaining pills at the usual time (even if it means taking two pills on the same day). Use back-up contraception (e.g., condoms) or avoid sexual intercourse until hormonal pills have been taken for 7 consecutive days. If pills were missed in the last week of hormonal pills (e.g., days 15-21 for 28-day pill packs): - Omit the hormone-free interval by finishing the hormonal pills in the current pack and starting a new pack the next day. - If unable to start a new pack immediately, use backup contraception (e.g., condoms) or avoid sexual intercourse until hormonal pills from a new pack have been taken for 7 consecutive days.
- Emergency contraception should be considered if hormonal pills were missed during the first week and unprotected sexual intercourse occurred in the previous 5 days.
- Emergency contraception may also be considered at other times as appropriate.

**153. 36 weeks pregnant female on warfarin with mitral stenosis. What should we do**

- A. Shift to LMW Heparin
- B. Warfarin
- C. Switch to Aspirin



D. Aspirin + heparin

**Answer: A Shift to LMW Heparin**

**Explanation**

Heart valve replacement with a prosthetic mechanical valve requires lifelong anticoagulation. The literature recommends switching to a LMWH for anticoagulation from the beginning of pregnancy through the first 12 weeks (end of first trimester). LMWH is preferred during the first trimester as it does not cross the placenta.

**154. Indomethacin when given beyond 36 weeks what will happen**

- A. Premature closure of PDA
- B. Still birth
- C. No effect
- D. Teratogenic

**Answer: A Premature closure of PDA**

**Explanation**

Pharmacological closure by indomethacin is customary if symptoms of PDA are not controlled adequately with fluid restriction and diuretics. Its use, however, requires a comprehensive clinical assessment of all the vital perinatal factors and a vigilant monitoring of the sick infant. Prophylactic use of indomethacin is discouraged.

**155. A pt. 2nd degree cervical prolapse C/o dribbling of urine on cough**

- A. Stress incontinence
- B. Overflow incontinence
- C. Cystitis
- D. Functional incontinence

**Answer: A Stress incontinence**

### Explanation

- If it deteriorates enough, the bladder can prolapse, meaning it is no longer supported and descends into the vagina. This may trigger problems such as urinary difficulties, discomfort, and stress incontinence (urine leakage caused by sneezing, coughing, and exertion, for example).
  - Urinary incontinence is the unintentional loss of urine. Stress incontinence happens when physical movement or activity — such as coughing, laughing, sneezing, running or heavy lifting — puts pressure (stress) on your bladder, causing you to leak urine.
- 

### 156. What does umbilical artery do

- A. Carrying deoxygenated blood from fetus to placenta
- B. Carrying oxygenated blood from placenta to fetus
- C. Provide nutrients
- D. None of the above

**Answer: A Carrying deoxygenated blood from fetus to placenta**

### Explanation

The umbilical arteries carry deoxygenated blood from fetal circulation to the placenta. The two umbilical arteries converge together about at 5 mm from the insertion of the cord, forming a type of vascular connection called the Hyrtl's anastomosis.

---

## Peds

### 157. A child with rachitic changes in limbs, which was not responding to Vitamin D.

**Investigations done shows-**

**Calcium- 9.5mg/dl, Phosphorous- 1.6 mg/dl, ALP- 814 IU, Sr. PTH- 24.2.Sr. Electrolytes, Creatinine and blood gases- normal.Diagnosis?**

- A. Vitamin D dependent rickets type 1
- B. Vitamin D dependent rickets type 2

- C. Hypophosphatemic rickets
- D. Chronic renal failure

**Answer: C**

### **Hypophosphatemic rickets**

#### **Explanation**

- Hypophosphatemic rickets is a disorder of bone mineralization caused due to defects (inherited/acquired) in the renal handling of phosphorus.
- Rickets can be classified into two major groups: calcipenic and phosphopenic
- In the absence of apoptosis, the hypertrophic cells accumulate in the growth plate and form the rachitic bone.
- In phosphopenic rickets (hypophosphatemic rickets), phosphate deficiency is the primary defect that results most commonly from increased renal excretion of phosphate. It is associated with normal or slightly elevated serum parathyroid hormone (PTH).

---

### **158. Contraindicated vaccine in 3 months old with recurrent respiratory illness-**

- A. Inactivated polio
- B. Measles
- C. DPT
- D. DT

**Answer: B**

#### **Explanation**

MMR vaccine should not be administered to severely immunocompromised persons as it is LAIV.

---

### **159. In a child height for age < -2 SD likely cause is-**

- A. Chronic malnutrition
- B. Acute malnutrition
- C. Recent infection

D. No malnutrition

**Answer: A**

**Explanation**

Stunting is defined as low height-for-age. It is the result of **chronic or recurrent undernutrition**, usually associated with poverty, poor maternal health and nutrition, frequent illness and/or inappropriate feeding and care in early life.

---

**160. Child presents with myoclonus jerk, decrease performance in school. There is history of fever at the age of 1 year with rash. It is suggestive of-**

- A. Subacute sclerosing panencephalitis
- B. Mesial temporal sclerosis
- C. Polio
- D. Measles

**Answer: A**

**Explanation**

- Subacute sclerosing panencephalitis (SSPE) is a progressive neurological disorder of children and young adults that affects the central nervous system (CNS). It is a slow, but persistent, viral infection caused by defective measles virus.
  - Most youngsters with SSPE have a history of measles infection at an early age, usually younger than 2 years, followed by a latent period of 6 to 8 years.
  - The initial symptoms of SSPE are subtle and include mild mental deterioration (such as memory loss) and changes in behavior (such as irritability) followed by disturbances in motor function, including uncontrollable involuntary jerking movements of the head, trunk or limbs called myoclonic jerks. Seizures may also occur.
  - In advanced stages of the disease, individuals may lose the ability to walk, as their muscles stiffen or spasm.
- 

**161. Webbed neck, short stature, low posterior hairline. Diagnosis-**

- A. Turner syndrome

- B. Down's syndrome
- C. Patau syndrome
- D. Edwards syndrome

**Answer: A**

**Explanation**

In the female newborn, Turner syndrome can present with congenital lymphedema of the hands and feet, webbed neck, nail dysplasia, narrow and high-arched palate, and short fourth metacarpals or metatarsals. As they grow up, the girls develop short stature, "shield" chest with widely spaced nipples, webbed neck, low hairline at the base of the neck, cubitus valgus, and Madelung deformity of the forearm and the wrist

---

**162. A 12 year old boy presented with weak pulses in upper limbs. His BP was 90/60mmHg. He also had retinal haemorrhages. Most likely diagnosis is**

- A. PAN
- B. Microscopic polyangiitis
- C. Takayasu arteritis
- D. HSP

**Answer: C**

**Explanation**

Takayasu arteritis, also known as pulseless disease, occlusive thromboangiopathy, and Martorell syndrome.

- Clinical features
  - weakness or pain in your limbs
  - lightheadedness or dizziness
  - trouble concentrating
  - vision problems
  - high blood pressure
-

**163. A 10 year old male child presented with generalised edema. His cholesterol was 238mg/dl and urine protein was 3+. Stool microscopy showed fat in stool.**

- A. Goodpasture syndrome
- B. Urine infection
- C. Nephrotic syndrome
- D. Nephritic syndrome

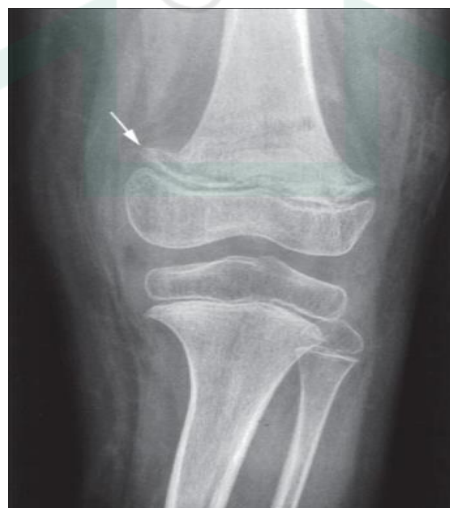**Answer: C**

**Explanation**

Nephrotic syndrome is the combination of nephrotic-range proteinuria with a low serum albumin level and edema. Nephrotic-range proteinuria is the loss of 3 grams or more per day of protein into the urine or, on a single spot urine collection, the presence of 2 g of protein per gram of urine creatinine.

---

**164. X-ray of a 5 year old child is shown in the image below. Bone mineral density is normal. Identify the condition.**

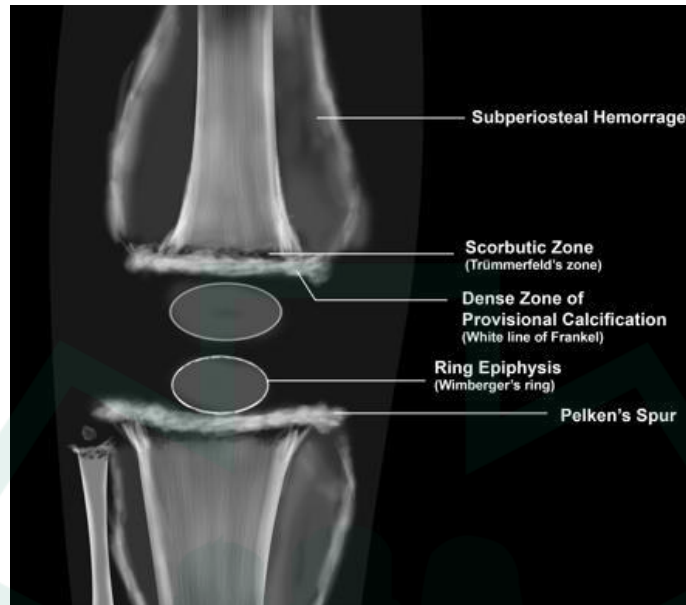

- A. Rickets
- B. Scurvy
- C. Metaphyseal dysplasia

D. Osteopetrosis

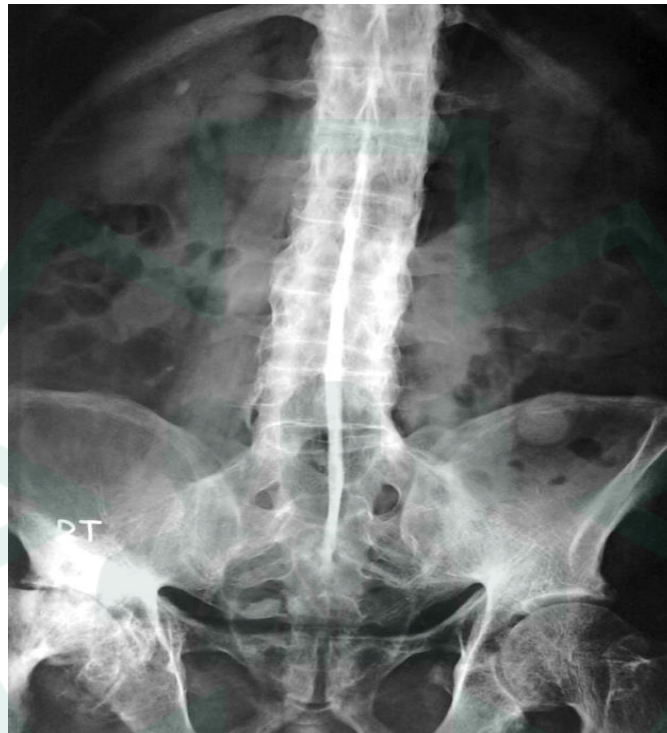Answer: B

Explanation



## Ortho

165. A 26 years old male with backache, morning stiffness, chest expansion and reddening of eyes with an X-ray presented in OPD. Most likely diagnosis for this patient is



- A. Rheumatoid arthritis
- B. Ankylosing spondylitis
- C. Paget's disease
- D. Osteopetrosis

**Answer: B**

### Explanation

- Ankylosing spondylitis has a bamboo spine appearance.
- Progressive musculoskeletal, and often extraskeletal, signs and symptoms are characteristic of the disease.
- Spinal stiffness, immobility, and postural changes, especially hyperkyphosis, are also commonly seen.



**166. 60 year old elderly female with previous h/o colles fracture is complaining of backache. Which of the given statement is wrong in relation to treatment of this patient**

- A. Teriparatide should be started before supplementing bisphosphonates
- B. Bisphosphonates not given for more than a year
- C. Calcium requirement is 1200mg per day
- D. Oral vit D3 given along with orl calcium

**Answer: A** Teriparatide should be started before supplementing bisphosphonates

**Explanation**

Antiresorptive agents such as bisphosphonates, which suppress bone turnover by inhibiting osteoclast activity, are commonly used prior to teriparatide as treatment for osteoporosis

---

**167. A patient fell down from bicycle & started having pain around hip, shortening of limb & attitude was flexion, adduction, IR of hip**

- A. Anterior dislocation
- B. Transcervical fracture
- C. Posterior dislocation
- D. IT Fracture

**Answer: C** Posterior dislocation

**Explanation**

The classic mechanisms of posterior dislocation involve tonic-clonic seizures, electrical shock, or anterior-directed shoulder trauma (such as a grabbing the dashboard in a motor vehicle collision or falling on an outstretched hand). These injuries create forceful internal rotation, adduction, and flexion of the shoulder. Posterior dislocations can be subclassified into three anatomic types based on the final resting position of the humeral head: (1) subacromial, the most common, (2)

subglenoid, and (3) subspinous. Posterior dislocations usually result in the humeral head being posterior to the glenoid and inferior to the acromion.

---

**168. A 20 year old patient presenting with chronic low backache and early morning stiffness since last 2 years. Since 6 months there are bilateral heel pain also. Most likely diagnosis for this patient is –**

- A. TB spine
- B. Ankylosing spondylitis
- C. Mechanical pain
- D. Disc prolapsed

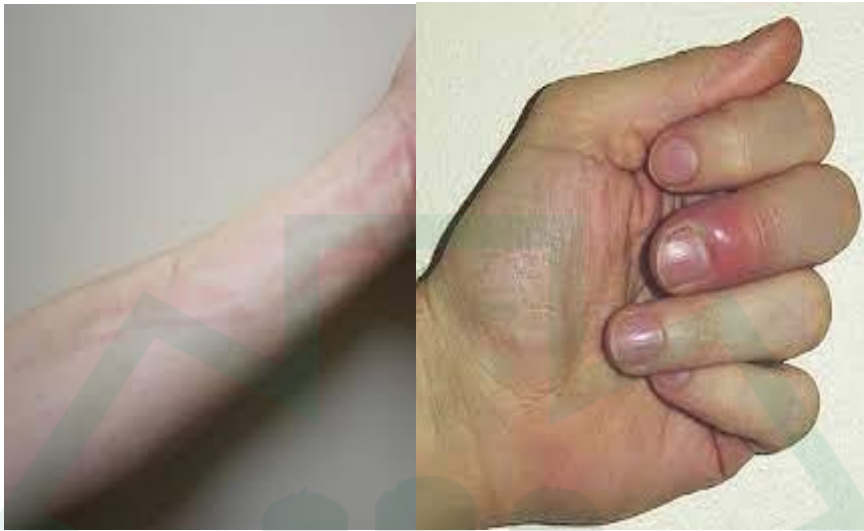**Answer: B**

**Explanation**

- Ankylosing spondylitis (AS) is a chronic inflammatory disease with an insidious onset. Progressive musculoskeletal, and often extraskeletal, signs and symptoms are characteristic of the disease.
  - The characteristic type of back pain in AS is "inflammatory" in nature. Inflammatory back pain typically exhibits at least four of the five following characteristics: age of onset less than 40 years, insidious onset, improvement with exercise, no improvement with rest, and pain at night with an improvement upon arising. Spinal stiffness, immobility, and postural changes, especially hyperkyphosis, are also commonly seen.
-

## Skin

169.



What is the most suitable antibiotic for this condition?

- A. Amoxicillin & Clavulanic acid
- B. Amikacin
- C. Norfloxacin
- D. Metronidazole

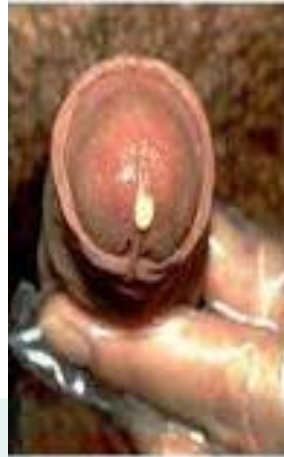**Answer: A**

### Explanation

Erysipelas is a common skin condition involving the upper dermis and extending into the superficial lymphatics of the skin. It is characterized by raised, well defined, tender, bright red rash. The causative organism is *Streptococcus pyogenes*, also known as A beta haemolytic streptococci. It is treated with penicillin group of drugs, which include amoxicillin-clavulanic acid.

---

170. A male patient came to OPD with White Discharge from urethra [Image Shown]. What is the most probable organism involved



- A. *Neisseria gonorrhoeae*
- B. *Haemophilus ducreyi*
- C. *Calymmatobacterium granulomatis*
- D. *Treponema pallidum*

**Answer: A** *Neisseria gonorrhoeae*

**Explanation**

*Neisseria gonorrhoeae* causes gonococcal infection in both males and females. Males are symptomatic for this infection while females remain asymptomatic and act as the reservoirs or carriers of infection. It sometimes presents as endocervicitis in females.

---

**171. A woman, anxious to conceive, complains of profuse white discharge per vaginum, which was non foul smelling and not itchy. Her LMP was 13-15 days back. What is the most probable diagnosis?**

- A. Candidiasis
- B. Bacterial Vaginosis
- C. Physiological
- D. Trichomoniasis

**Answer: C** Physiological

**Explanation**

The amount and consistency of vaginal discharge changes with the menstrual cycle. In the days right after menstruation, vaginal discharge is minimal, and its consistency is thick and sticky. When approaching ovulation, the rising estrogen levels cause a concomitant increase in vaginal discharge. The amount of discharge produced at ovulation is 30 times greater than the amount produced directly following menstruation. The discharge also changes in color and consistency during this time, becoming clear with an elastic consistency.

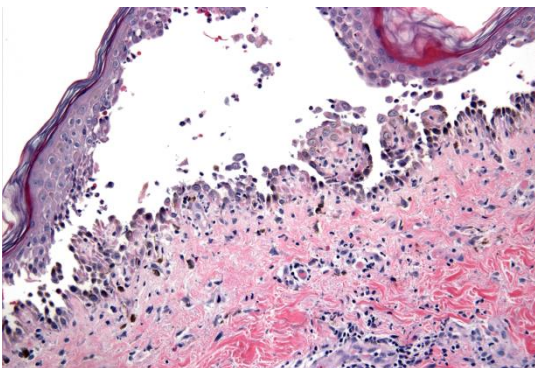
**172. A 30 year old woman came with flaccid bullae on her skin which were easy to rupture. Biopsy of the lesion revealed a suprabasal split. What is the most likely diagnosis?**

- A. Pemphigus vegetans
- B. Pemphigus vulgaris
- C. Pemphigus foliaceus
- D. Erythema multiforme

**Answer: B** Pemphigus vulgaris

**Explanation**

Histopathology demonstrates an intradermal blister. The earliest changes consist of intercellular edema with loss of intercellular attachments in the basal layer. Suprabasal epidermal cells separate from the basal cells to form clefts and blisters. Basal cells are separated from one another and stand like a row of tombstones on the floor of the blister, but they remain attached to the basement membrane. Blister cells contain some acantholytic cells. Histopathology can help differentiate pemphigus vulgaris from pemphigus foliaceus, which demonstrates a more superficial epidermal cleavage.



**173. A patient who has been on MBMDT presents with inflammation over pre-existing lesions and nerve involvement. What will be the best approach of treatment?**

- A. Stop ALT and start steroids
- B. Stop ALT and start thalidomide
- C. Continue ALT and start steroids
- D. Continue ALT and give thalidomide

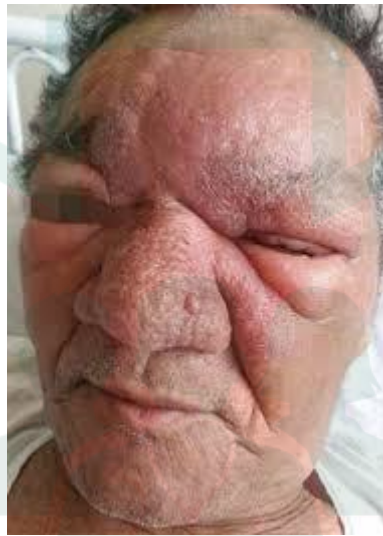**Answer: C Continue ALT and start steroids**

#### **Explanation**

- This is a presentation of Lepra Reaction. In both the types of Lepra reactions, ALT should be continued and steroids must be started for the management.
- Type 1 reactions are due to changes in cell-mediated immunity (CMI) to the infectious agent *Mycobacterium leprae*. Type 1 reactions may occur in any subtype of leprosy, but patients with borderline leprosy are most frequently affected. Patients present with increased erythema, edema, and warmth of preexisting cutaneous plaques and nodules. There is often accompanying edema of the hands and feet. New ulcerations of preexisting lesions may also occur, as well as the formation of new plaques. Additionally, there may be swelling and tenderness of peripheral nerves and loss of neurologic function. Systemic symptoms are uncommon. This reaction may be seen after pregnancy or immunosuppressive treatment. It may also occur in patients co-infected with human immunodeficiency virus (HIV) within months of starting antiretroviral therapy.
- The type 2 reaction is also known as erythema nodosum leprosum. Patients present with sudden onset crops of painful, tender, and erythematous subcutaneous nodules that may subsequently ulcerate. The lesions are common on the face and extensor surfaces of the upper and lower extremities. In addition, there may be systemic signs such as fever, malaise, arthralgias, and myalgias. Other affected organs may include the eyes, kidneys, testes, and lymph nodes. Type 2 reactions are caused by immune complex formation and deposition. They typically are seen in patients with borderline lepromatous or polar

lepomatous disease. Reactions may last from days to weeks; they may recur or persist over months.

**174. A 13 year old male presented with erythematous edematous plaques on face over his previously existing hypoanaesthetic patches. He also complained of pain since 10 days. He has been on MBMDT since the past 2 months. What is your diagnosis?**



- A. Cellulitis of face
- B. Type 1 lepra reaction
- C. Erythema Nodosum Leprosum
- D. Erysipelas

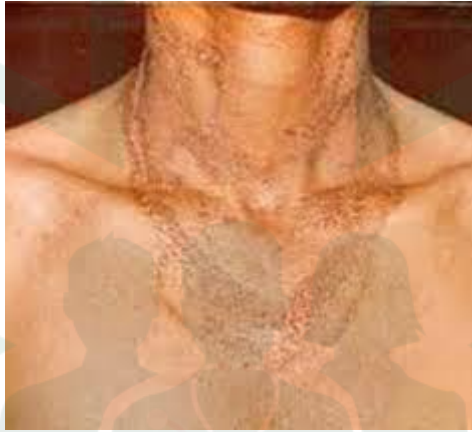**Answer: B** Type 1 lepra reaction

### **Explanation**

- Type 1 reactions are due to changes in cell-mediated immunity (CMI) to the infectious agent *Mycobacterium leprae*. Type 1 reactions may occur in any subtype of leprosy, but patients with borderline leprosy are most frequently affected. Patients present with increased erythema, edema, and warmth of preexisting cutaneous plaques and nodules.

- There is often accompanying edema of the hands and feet. New ulcerations of preexisting lesions may also occur, as well as the formation of new plaques. Additionally, there may be swelling and tenderness of peripheral nerves and loss of neurologic function.
  - Systemic symptoms are uncommon. This reaction may be seen after pregnancy or immunosuppressive treatment. It may also occur in patients co-infected with human immunodeficiency virus (HIV) within months of starting antiretroviral therapy.
- 

**175. What are the associated features of this deficiency disorder?**



- A. History of diarrhoea & dementia associated with cognitive impairment
- B. Bitot's spots
- C. Angular stomatitis
- D. Loss of muscle coordination

**Answer: A** History of diarrhoea & dementia associated with cognitive impairment

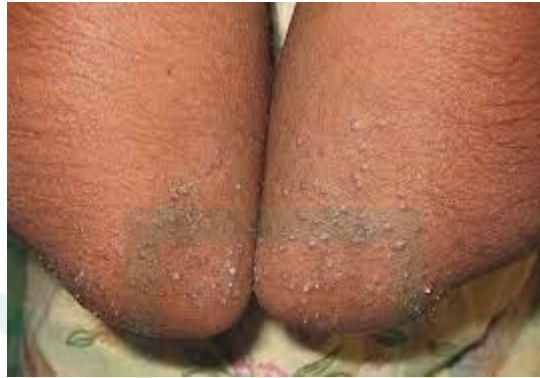**Explanation**

The image shows "Casal's Necklace" which is a classical manifestation of Pellagra due to Niacin, i.e., Vitamin B3 deficiency. Pellagra is clinically manifested by the 4 *D*'s: photosensitive dermatitis, diarrhea, dementia, and death. This is the only photosensitivity syndrome where death is included as a cardinal clinical feature. The full tetrad of symptoms is usually not well developed in infants and children. This vitamin deficiency responds to treatment with nicotinic acid.

---



176. A young girl presented to the OPD with rough surfaced lesions over her elbows and knees. She also complained of diminished vision in the night. What is the most likely diagnosis?



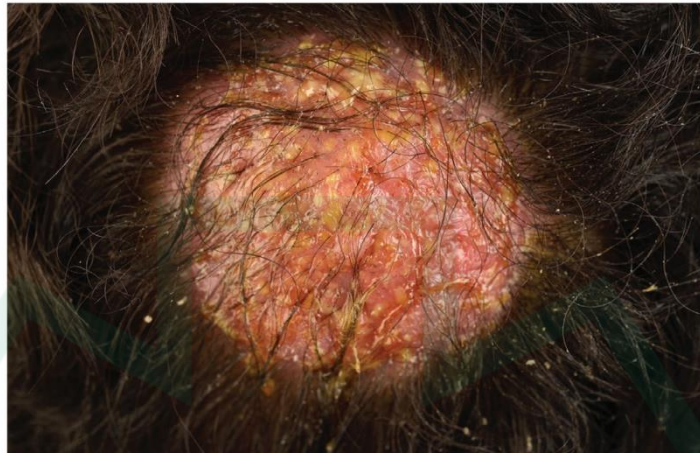- A. Keratosis pilaris
- B. Phrynoderma
- C. Folliculitis
- D. Pyoderma

**Answer: B** Phrynoderma

**Explanation**

- This is a case of Phrynoderma.
- Phrynoderma is a form of follicular hyperkeratosis that is associated with nutritional deficiencies. It is endemic to poor populations but is rare in developed countries.
- The term “phrynoderma” was coined by Nicholls in 1933 to describe the “toad-like” appearance of the skin of undernourished labourers. This form of dermatosis can be caused by isolated deficiencies of vitamins A, B complex, C and E. Adjunctive symptoms, such as cheilitis, glossitis, blepharitis, night blindness, diarrhea, muscle weakness and neuritis, may develop when hypovitaminosis A is predominant relative to other vitamin deficiency

177. A male child was brought with a mild painful swelling on his scalp since the last 3 months, as shown in the image below. History reveals that there is a pet dog in the child's house. What is the diagnosis?



- A. Folliculitis
- B. Abscess
- C. Kerion
- D. Scabies

**Answer:** C Kerion

### Explanation

- Kerion is an acute inflammatory process which is the result of the host's response to a fungal ringworm infection of the hair follicles of the scalp (occasionally the beard) that can be accompanied by secondary bacterial infection.
- It usually appears as raised, spongy lesions, and typically occurs in children.
- This honeycomb is a painful inflammatory reaction with deep suppurative lesions on the scalp. Follicles may be seen discharging pus.
- There may be sinus formation and rarely mycetoma-like grains are produced. It is usually caused by dermatophytes (fungal infections of the skin affecting humans and animals) such as *Trichophyton verrucosum*, *T. mentagrophytes*, and *Microsporum canis*. Treatment is with oral griseofulvin.

**178. A 23 year old primi gravida stays in the same house as her school going nephew, who contracted varicella infection. The woman approached the medical centre to get tested for the same and the result for varicella antibody was negative. Which of the following statements are true?**

- A. She is susceptible to zoster
- B. She is susceptible to chickenpox
- C. She is immune to chickenpox
- D. She is immune to zoster


**Answer: B**

**Explanation**

- Varicella zoster causes 2 diseases in the infected persons; varicella(chickenpox) and zoster. Chickenpox or Varicella is a childhood disease.
- Zoster is the reactivation of this disease in adults. As a rule, the first episode of infection always manifests as chickenpox.
- In the given question, the pregnant lady is negative for varicella antibodies, indicating that she has not been infected even once in her life time.
- Hence she is susceptible to contracting chickenpox from her contact.

---

**179. Hair perforation test is positive for**



- A. Trichophyton mentagrophytes
- B. Microsporum adouinii
- C. Epidermophyton floccosum
- D. Microsporum gypsum

**Answer: A** Trichophyton mentagrophytes

### Explanation

Hair perforation test is done for dermatophytes, particularly Trichophyton mentagrophytes and its variants.

#### Ingredients:

- Autoclaved blonde prepubital hair cut into small pieces
- 5ml sterile distilled water in suitable vial

#### Procedure:

- Place hair in the vial
- Inoculate the test fungus into the hair in the vial
- Incubate at room temperature
- Individual hairs are removed at intervals upto 4 weeks and examined microscopically in lactophenol cotton blue.

---

## Anesthesia

**180. A 30 year old male was intubated for surgery. The best method to confirm the position of Endotracheal tube is**

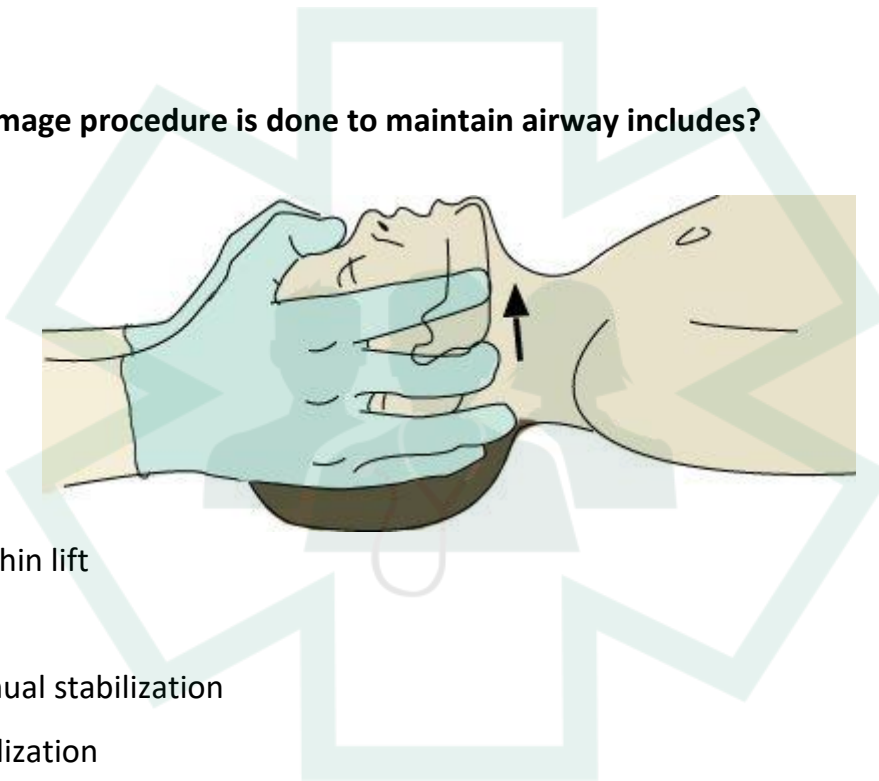
- A. X-ray chest
- B. Auscultation
- C. Capnography
- D. Chest expansion

**Answer: C**

**Explanation**

- Use an **end-tidal carbon dioxide detector (i.e., continuous waveform capnography, colorimetric and non-waveform capnography)** to evaluate and confirm endotracheal tube position in patients who have adequate tissue perfusion.
  - Capnography is the most reliable method to confirm endotracheal tube placement in emergency conditions in the prehospital setting.
- 

**181. The below image procedure is done to maintain airway includes?**



- A. Head tilt, chin lift
- B. Jaw thrust
- C. In line manual stabilization
- D. Head stabilization

**Answer: A**

**Explanation**

The triple airway manoeuvre is **used to maintain a patent upper airway and combines head tilt, jaw thrust and mouth open.**

---

**182. A young male was given regional anaesthesia with 0.25% bupivacaine. The pt. Become unresponsive & pulse become unrecordable. Best Management would be**

- A. CPR with 20% Intralipid
- B. CPR with sod. Bicarbonate
- C. CPR with dobutamine
- D. CPR with calcium

**Answer: A**

**Explanation**

Patient will be started with CPR as patient became unresponsive and pulse became unrecordable and should be given antidote Intralipid 20%

---

**183. While doing lumbar puncture, last structure to be encountered will be in a patient who presented with fever, neck rigidity & altered sensorium**

- A. Arachnoid membrane
- B. Ligamentum flavum
- C. Dura mater
- D. Pia mater

**Answer: A**

**Explanation**

The Lumbar Puncture needle pierces in order: **skin, subcutaneous tissue, supraspinous ligament, interspinous ligament, ligamentum flavum**, epidural space containing the internal vertebral venous plexus, dura, arachnoid, and finally the subarachnoid space.

---

**184. A pt. Is undergoing surgery where anaesthesia is maintained on halothane. The pt. Developed hyperthermia & m/s rigidity. Which of the agents is responsible?**

- A. D-tubocurarine
- B. Suxamethonium
- C. Cisatracurium
- D. Rocuronium

**Answer: B**

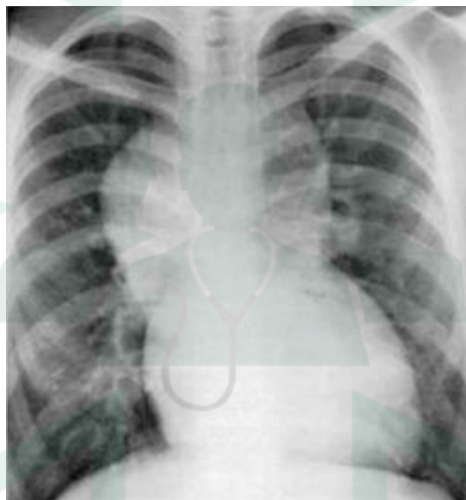
**Explanation**

This patient has developed malignant hyperthermia. And the MC agent to trigger this condition is Suxamethonium

---

## Radiology

185. A child present with cyanosis. Diagnosis is



- A. Cottage loaf heart, Truncus arteriosus
- B. Snowman heart, supracardiac TAPVC
- C. Egg on side, TGA
- D. Boot shaped heart, TOF

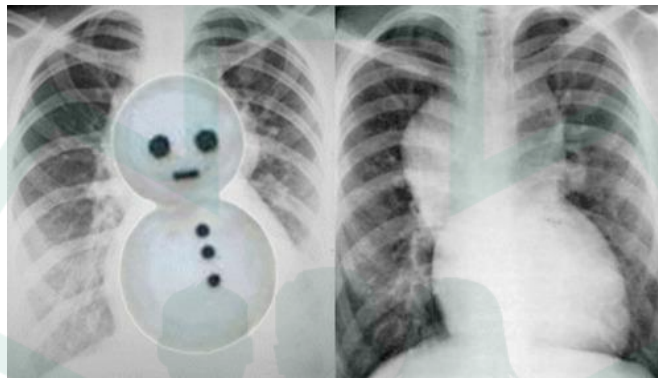
**Ans. is b i.e. Snowman heart, supracardiac TAPVC**

**Explanation**

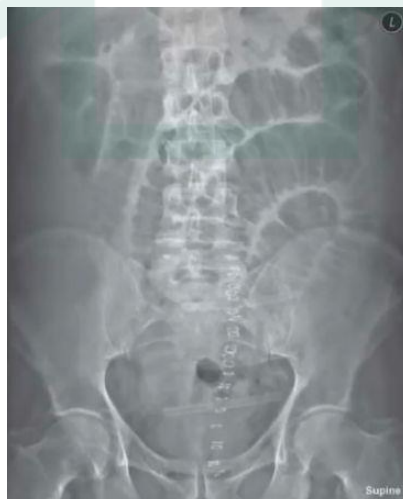Snowman sign refers to the configuration of the heart and the superior mediastinal borders resembling a snowman. This is seen in total anomalous pulmonary venous return (TAPVR) type I (supracardiac type). It is also referred to as the figure of 8 sign.

It is an abnormality of the fetal circulation wherein the entire pulmonary venous flow is directed to the right atrium via the superior vena cava (SVC). All pulmonary veins join to form a common pulmonary vein which drains into a vertical vein. The vertical vein drains into the SVC via the innominate (brachiocephalic) vein.

The paratracheal shadow on the right is the prominent SVC and on the left is the vertical vein. The innominate vessel lies in the midline above base of heart. These three prominent vessels together form the head of the 'snowman'. The body is formed by the rest of the heart.



**186. A patient presents with abdominal pain & Distension. Dilated Bowel loops are:**



- A. Jejunum
- B. Duodenum
- C. Ileum



D. Transverse colon

**Ans. is a. i.e. Jejunum**

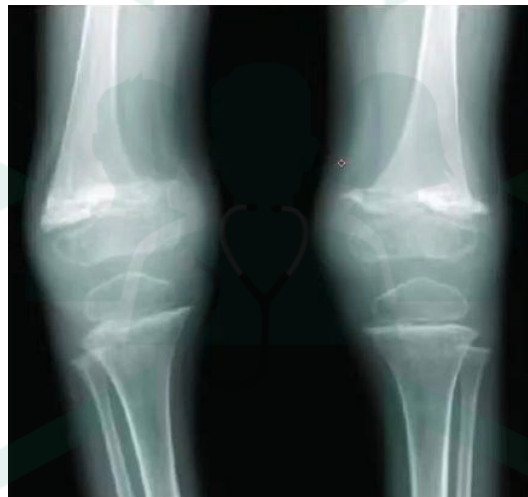**Explanation**

Small bowel obstruction (SBO) accounts for 80% of all mechanical intestinal obstruction, the remaining 20% results from a large bowel obstruction. It has a mortality rate of ~5%.

Classical presentation is cramping abdominal pain and abdominal distension with nausea and vomiting. Radiographic findings can be evident 6-12 hours before the onset of clinical symptoms

---

**187. A 10 year old child presents with limb pain. Bone mineral density is normal. Diagnosis**



- A. Scurvy
- B. Rickets
- C. Pyknodysostosis
- D. Metaphyseal Dysplasia

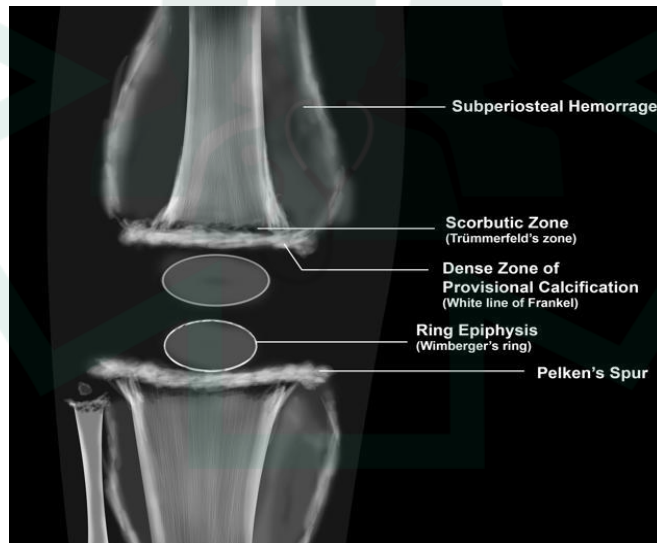**Ans. is a i.e. Scurvy**

**Explanation**

**Radiographic features**

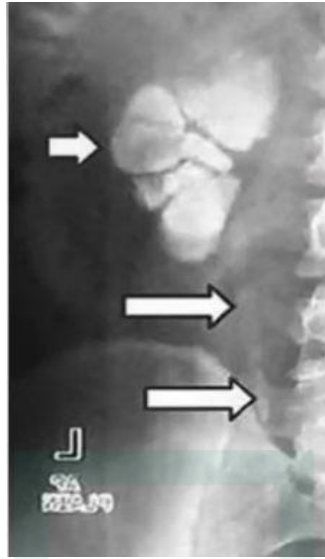
**Pediatric**

- generalized osteopenia
- cortical thinning: “pencil-point” cortex
- periosteal reaction due to subperiosteal hemorrhage
- scorbutic rosary: expansion of the costochondral junctions
  - may relate to the fracturing of the zone of provisional calcification during normal respiration
  - similar to the rachitic rosary appearance as seen in rickets
- hemarthrosis
- Wimberger ring sign: circular, opaque radiologic shadow surrounding epiphyseal centers of ossification, which may result from bleeding
- Frankel line: dense zone of provisional calcification
- Trümmerfeld zone: lucent metaphyseal band underlying Frankel line
- Pelkin spur: metaphyseal spurs that result in cupping of the metaphysis
- Pelkin fracture: metaphyseal corner fracture



---

**188. A 30 year old female with sterile Pyuria. Radiograph is shown. Diagnosis is**



- A. Nephrocalcinosis
- B. Putty Kidney
- C. Stag horn calculus
- D. Psoas Calcification

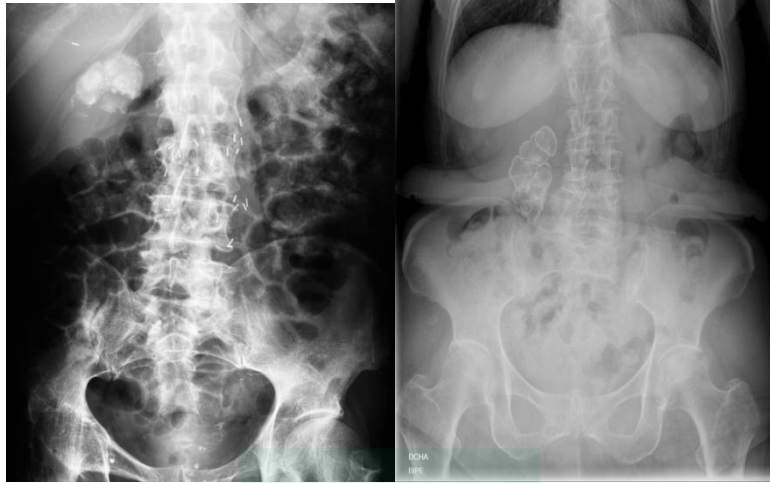**Ans. is b i.e. Putty Kidney**

**Explanation**

A putty kidney refers to a pattern of renal calcification associated with renal tuberculosis conventionally described on plain radiography. The calcification is characteristically very homogeneous and ground glass-like, representing calcified caseous tissue.

Premkumar et al. labeled calcification 'putty-like' if any faint area of uniform calcification was more than 1 cm in diameter.

Putty calcification needs to be differentiated from a lobar pattern of calcification, wherein dense calcific rims outline the periphery of distorted renal lobes. Lobar calcification represents an end-stage appearance, associated with autonephrectomy.



---

**189. A child undergoes prophylactic irradiation as preparation for BMT for treatment of ALL. Which of the following will be least affected?**

- A. Spermatogonia
- B. Intestinal epithelial cells
- C. Neurons
- D. Bone marrow

**Ans. is c i.e. Neurons**

**Explanation**

The law of Bergonie and Tribondeau is that the radiosensitivity of a biological tissue is directly proportional to the mitotic activity and inversely proportional to the degree of differentiation of its cells.

---

**190. RTA- absent air entry on left side. Tenderness in left lower chest wall. Next step in EMR**

- A. X-ray
- B. CT
- C. FAST
- D. DPL

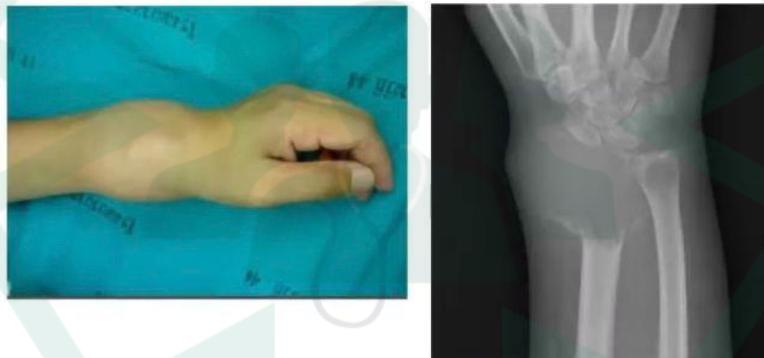**Ans is c. FAST**

**Explanation**

Focused Assessment with Sonography for Trauma (FAST) scan is a point-of-care ultrasound examination performed at the time of presentation of a trauma patient.

The chief aim of the study, in a trauma patient, is to identify intraperitoneal free fluid (assumed to be hemoperitoneum in the context of trauma) allowing for an immediate transfer to theater, CT or other. Solid organ injury is seldom identified, and when present may warrant further investigation.

**191. Diagnosis**



- A. GCT
- B. Osteochondroma
- C. Osteoid Osteoma
- D. Ewings Sarcoma

**Ans. is a. GCT**

**Explanation**

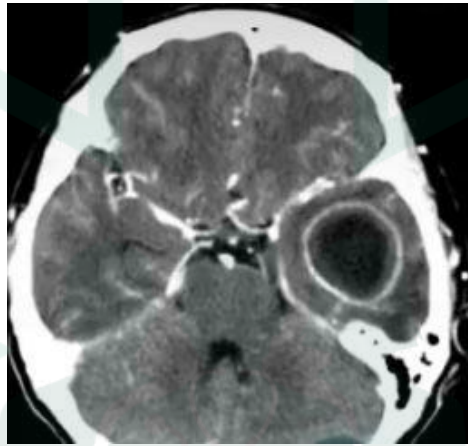
Tenosynovial giant cell tumors are usually benign lesions that arise from the tendon sheath. It is unclear whether these lesions represent neoplasms or merely reactive masses. On imaging, these lesions are commonly demonstrated as localized, solitary, subcutaneous soft tissue nodules, with low T1 and T2 signal and moderate enhancement.

Typically, they present in the 3rd to 5th decades and have a slight female predilection with an F:M ratio of 1.5-2.1:1. They are the second most common soft tissue mass of the hand and wrist.

Clinically these masses generally present in the hand (although they are found elsewhere also) as localized swelling with or without pain. They are slow-growing.

---

**192. A patient with ear discharge**



- A. Cerebellar abscess
- B. Temporal lobe abscess
- C. Extradural abscess
- D. Meningitis

**Ans. is b i.e. Temporal lobe abscess**

**Explanation**

Temporal lobe abscesses frequently arise from middle ear mixed bacterial infections, with large numbers of anaerobes.

Although mortality appears to be decreasing, a significant percentage of children continue to have residual neurological deficits, including epilepsy, permanent motor or sensory dysfunction, visual field defects, and personality change.

Some children also require placement of a ventriculoperitoneal shunt. The most common origin of microbial infection in children remains direct or indirect cranial infection arising from the middle ear, paranasal sinuses, or teeth.

---

**193. Infertility patient-USG s/o uterine anomaly. Best to confirm**

- A. TVS
- B. Hysteroscopy + Laparoscopy
- C. HSG
- D. Laparoscopy

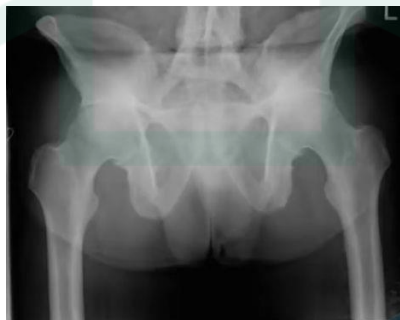**Ans is b i.e. Hysteroscopy + Laparoscopy**

**Explanation**

Hysteroscopy-laparoscopy is diagnostic and therapeutic both for uterine, tubal infertility and ovarian abnormalities. They give an advantage in diagnosis and treatment of female infertility at the same sitting.

---

**194. A 50yr old male with backache & morning stiffness, red eye, ankle swelling**



- A. Ankylosing Spondylitis
- B. Healed TB spine
- C. Pagets
- D. Osteopetrosis

**Ans. is a i.e. Ankylosing Spondylitis**

### Explanation

Ankylosing spondylitis symptoms vary widely. Pain is always a symptom but the location and quality of pain can be different from person to person. Pain is typically accompanied by other symptoms, such as fatigue or eye irritation.

### Radiographic features:- Spine

- early spondylitis is characterized by small erosions at the corners of vertebral bodies with reactive sclerosis: Romanus lesions of the spine (shiny corner sign)
- vertebral body squaring
- noninfectious spondylodiscitis: Andersson lesion
- diffuse syndesmophytic ankylosis can give a "bamboo spine" appearance syndesmophytes are classically described as paravertebral ossification running parallel to the spine
- linear ossification along the central spine; representing interspinous ligament ossification can give a "dagger spine" appearance on frontal radiographs;
- ossification of spinal ligaments, joints and discs (with fatty marrow within the ossified disc, best seen on MRI)
- apophyseal and costovertebral arthritis and ankylosis
- enthesophyte formation from enthesopathy
- pseudoarthroses may form at fracture sites
- dural ectasia

**195. A mother gets her daughter with short stature, webbing of neck etc. USG will show**

- Hepatomegaly with altered echotexture
- Single kidney
- Echo showing tricuspid stenosis
- Streak ovaries with small uterus

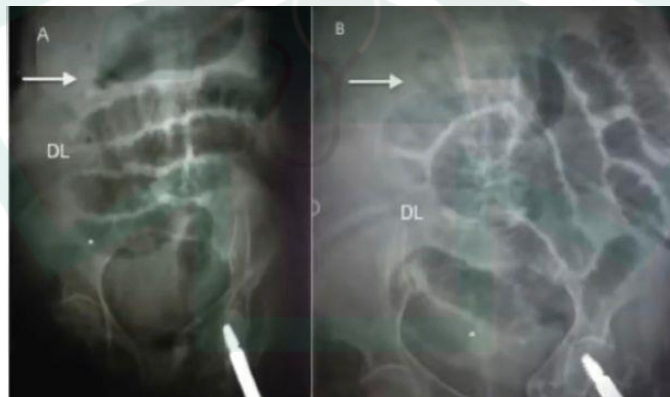
**Ans. is d i.e. Streak ovaries with small uterus**

### Explanation



- Turner syndrome is a genetic disorder affecting girls and women.
- The cause of Turner syndrome is a completely or partially missing X chromosome.
- Turner syndrome symptoms include short stature and lack of breast development and periods.
- Treatment for Turner syndrome may include hormone therapy.
- Patients are usually females and present with streak ovaries that leads to primary amenorrhea or premature ovarian failure.
- The ovaries usually develop normally at first, but the egg cells die prematurely and most of the ovarian tissue degenerates before birth.
- In most of the females, hormonal therapy is required for attaining menarche and development of secondary sexual characters.
- There will be streak ovaries but the uterus, fallopian tube, vagina will be developed normally. In almost 95% of cases there will be short stature and loss of ovarian function.

**196. A 60 yr old obese female presents with abdominal pain, distension, there are increased bowel sounds. There are multiple air fluid levels & there was air in biliary tree. Also there was a H/o hysterectomy 2 years back. Probable diagnosis is**



- a. Gall stone ileus
- b. Small bowel obstruction
- c. Large bowel obstruction
- d. Paralytic ileus

**Ans. is a i.e. Gall stone ileus**

**Explanation**

- Rigler's triad is a combination of findings on an abdominal radiograph of people with gallstone ileus, a condition where a large gallstone causes bowel obstruction.
  - Rigler's triad consists of: (1) small bowel obstruction, (2) a gallstone outside the gallbladder, and (3) air in the bile ducts.
  - Gallstone ileus is an uncommon cause of a mechanical small bowel obstruction.
  - It is a rare complication of chronic cholecystitis and occurs when a gallstone passes through a fistula between the gallbladder and small bowel before becoming impacted at the ileocecal valve.
  - Pneumobilia, also known as aerobilia, is the accumulation of gas in the biliary tree.
  - It is important to distinguish pneumobilia from portal venous gas, the other type of branching hepatic gas.
  - There are many causes of pneumobilia and clinical context is often important to distinguish between these
- 

**197. A 45 year old patient with hypertension presenting with acute severe chest pain & there is diaphoresis. Also there is h/o loss of consciousness, unequal pulses. In emergency condition which is the best one to make a diagnosis**

- A. Cardiac enzymes
- B. MRI
- C. X-ray
- D. TEE

**Ans. is d i.e. TEE**

**Explanation**

A standard transesophageal echocardiography (TOE, or TEE in US English) is a type of ultrasound using an endoscopic transducer, which is advanced into the esophagus, offering generally superior visualization of the great vessels and posterior cardiac structures than the standard transthoracic approach (TTE). TOE is most frequently used in specialties such as anesthesia, cardiology, and critical care, for evaluation of cardiac and aortic structures.

---

**198. A female presenting with abdominal pain, distension, organ failure in last 24 hours. CT scan shows pancreas which is bulky & there is fluid density lesion in the pancreas. Which of the following will be increased.**

- A. AST
- B. Lipase
- C. Creatine Kinase
- D. Blood Urea Nitrogen

**Ans. is b. Lipase**

**Explanation**

Blood amylase and lipase levels are most frequently drawn to diagnose pancreatitis. When the pancreas is inflamed, increased blood levels of the pancreatic enzymes called amylase and lipase will result.

---

**199. There was patient of Kidney trauma with hematuria. Which of the following investigation is advised to localised the site of hematuria**

- A. CT
- B. X-ray
- C. MRI
- D. USG

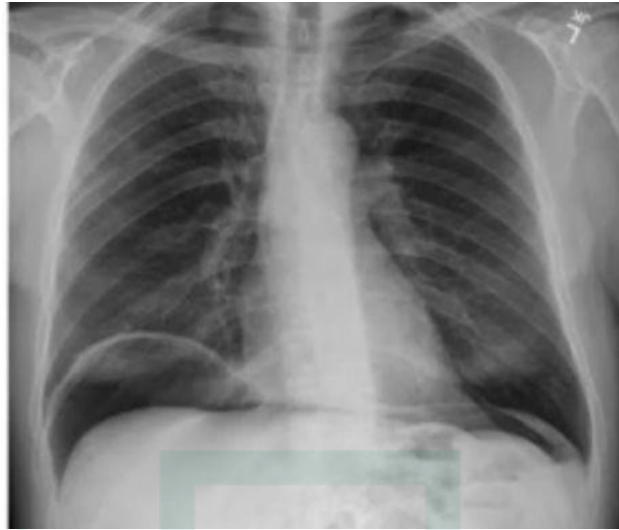**Ans. is a i.e. CT**

**Explanation**

Recommended investigations for haematuria include computed tomography intravenous pyelogram, urine cytology, urine microscopy and culture and blood tests (full blood examination, renal function and, in men, prostate-specific antigen).

---

**200. 2 X-rays (Erect & Supine) were given to identify the condition**

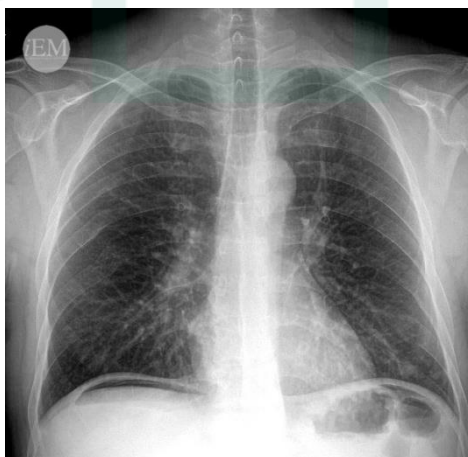

- A. Empyema Thorax
- B. Liver abscess
- C. Gastric volvulus
- D. Hollow viscus perforation

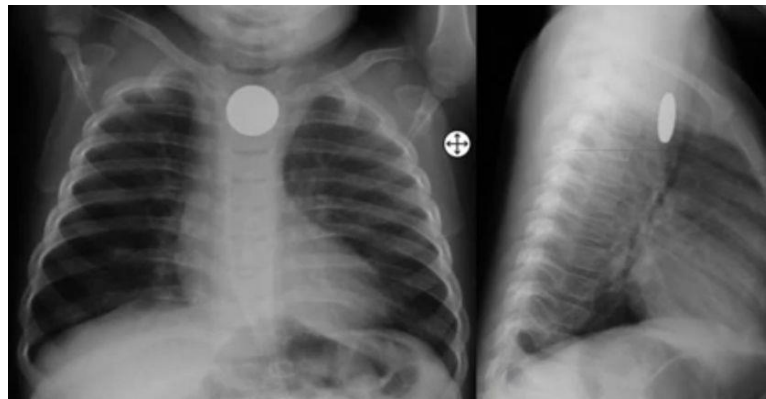
**Ans. is d. i.e. Hollow viscus perforation**

**Explanation**

Perforated hollow viscus is characterized by loss of gastrointestinal wall integrity with subsequent leakage of enteric contents. Direct trauma or tissue ischemia and necrosis lead to full-thickness disruption of the gastrointestinal wall and perforation.



**201. A baby playing was left unattended by the mother develops distress. Identify where the object is**



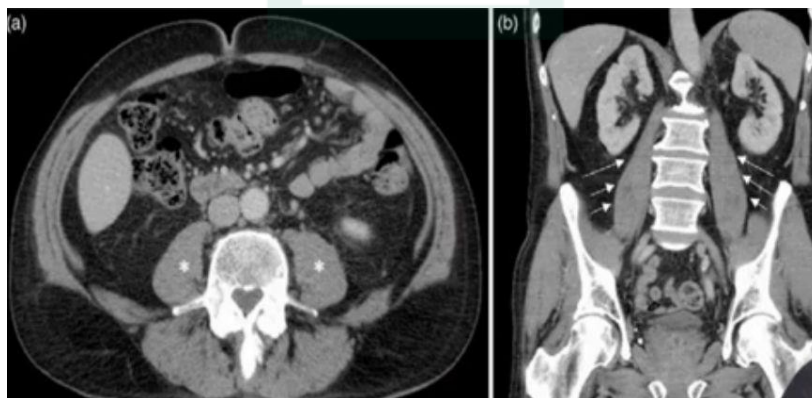- A. Oesophagus
- B. Trachea
- C. Below diaphragm
- D. GI tract

**Ans. is a. i.e. Oesophagus**

**Explanation**

A round metallic foreign body lies in the midline just above the aortic knob, suggestive of a coin within the esophagus, the coin exceeds the diameter of the trachea, also on the lateral view, the trachea appears anterior to the coin, so that it can not lie within it.

**202. Identify the muscle marked causes flexion of hip**



- A. Gluteus Muscle
- B. Psoas Muscle

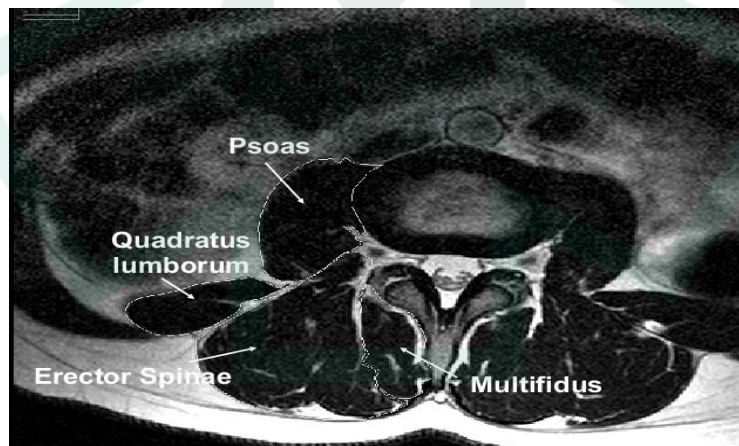
- C. latissimus dorsi
- D. Multifidus

**Ans. is b i.e. Psoas Muscle**

### Explanation

The **psoas major muscle** (usually shortened to just the **psoas muscle**) is one of the muscles of the posterior abdominal wall and lies not in the retroperitoneum but posterior to it, in the iliopsoas compartment.

- **origin:** vertebral bodies, intervertebral discs and transverse processes of T12 to L5
- **insertion:** lesser trochanter of the femur
- **innervation:** branches of the L1-L3 roots of the lumbar plexus
- **arterial supply:** lumbar arteries, iliolumbar artery, deep circumflex iliac artery, external iliac artery, femoral artery
- **action:** lateral flexion of the trunk; stabilizer and flexor of the hip



## Psychiatry

**203. A 16 year old female patient presented with over familiarity, flight of ideas, elevated mood, increased sexual desire, pseudohallucinations. What will be the diagnosis?**

- A. Mania

- B. Schizomania
- C. Hypomania
- D. Cyclothymia

**Answer- A**

**Explanation**

Mania is a **psychological condition that causes a person to experience unreasonable euphoria, very intense moods, hyperactivity, and delusions**. Mania (or manic episodes) is a common symptom of bipolar disorder. Mania can be a dangerous condition for several reasons. People may not sleep or eat while in a manic episode.

---

**204. A 50 year old male suddenly stopped alcohol consumption for 3 days in hospital with agitation, altered sensorium, paranoid delusions and hallucinations. The most likely diagnosis is**

- A. Wernicke's Encephalopathy
- B. Korsakoff's psychosis
- C. Hangover
- D. Delirium Tremens

**Answer: D**Delirium Tremens

**Explanation**

Delirium tremens is the most severe form of ethanol withdrawal, manifested by altered mental status (global confusion) and sympathetic overdrive (autonomic hyperactivity), which can progress to cardiovascular collapse. Minor alcohol withdrawal is characterized by tremor, anxiety, nausea, vomiting, and insomnia. Major alcohol withdrawal signs and symptoms include visual hallucinations and auditory hallucinations, whole body tremor, vomiting, diaphoresis, and hypertension (high blood pressure).

---

**205. Which of the following is included in form of thought disorder**

- A. Derailment
- B. Obsession
- C. Thought insertion
- D. Delusion

**Answer- A**

**Explanation**

Types of thought disorder include derailment, pressured speech, poverty of speech, tangentiality, verbigeration and thought blocking.

---

**206. During the course of psychotherapy, the therapist has mixed conscious and unconscious feeling towards a patient, this is known as**

- A. Transference
- B. Countertransference
- C. Dissociation
- D. Preoccupation

**Answer- B**

**Explanation**

In psychoanalytic theory, counter-transference occurs **when the therapist projects their own unresolved conflicts onto the client**. This could be in response to something the client has unearthed. Although many now believe it to be inevitable, countertransference can be damaging if not appropriately managed.